

1. Centromere near the end of chromosome

a) Acrocentric

b) Metacentric

c) Submetacentric

d) Telocentric

Correct Answer - A

Acrocentric

Centromere positions

Each chromosome has two arms, labeled p (the shorter of the two) and q (the longer). The p arm is named for "petit" meaning 'small'; the q arm is named q simply because it follows p in the alphabet. ("q" refers to the French word "queue" meaning 'tail')

Metacentric: A chromosome is metacentric if its two arms are roughly equal in length. In some cases, a metacentric chromosome is formed by balanced Robertsonian translocation: the fusion of two acrocentric chromosomes to form one metacentric chromosome.

Example 1, 3, 16, 19, 20.

Submetacentric: If arms' lengths are unequal, the chromosome is said to be Submetacentric. Example-*X chromosome, 2, 4, 12, 17, 18*

Acrocentric: If the p (short) arm is so short that is hard to observe, but still present, then the chromosome is acrocentric (The "acro-" in acrocentric refers to the Greek word for "peak"). The human genome includes acrocentric *Y-chromosomes, 13, 14, 15, 21 and 22*

2. Nerve supply of circumvallate papillae is:

a) Hypoglossal nerve

b) Glossopharyngeal nerve

c) Lingual nerve

d) Chorda tympani

Correct Answer - B

Circumvallate papilla is one of the large papillae near the base on the dorsal aspect of the tongue arranged in a V-shape. The taste buds are located in the epithelium of the trench surrounding the papilla. Motor nerve supply of tongue: All the intrinsic and extrinsic muscles of the tongue are supplied by the hypoglossal nerve except the palatoglossus muscle which is supplied by the cranial part of the accessory nerve through the pharyngeal plexus.

Glossopharyngeal nerve is both general sensory and special sensory to the posterior 1/3rd of the tongue. Posterior most part of the tongue is supplied by the internal laryngeal nerve which is a branch of vagus nerve.

3. Structures passing through obturator foramen are all except -

a) Obturator nerve

b) Obturator artery

c) Obturator vein

d) Internal pudendal vessels

Correct Answer - D

Through the canal the obturator artery, obturator vein and obturator nerve pass out of the pelvis.

4. Contents of Adductor canal are all **EXCEPT:**

a) Femoral artery

b) Popliteal artery

c) Nerve to Vastus medialis

d) Saphenous nerve

Correct Answer - B

Popliteal artery

THE ADDUCTOR CANAL (Subsartorial/Hunter's canal) is an aponeurotic tunnel in the middle third of the thigh, extending from the apex of the femoral triangle to the opening in the Adductor magnus, the Adductor hiatus.

(Femoral artery, femoral vein and saphenous nerve go into this canal through superior foramen. Saphenous nerve and artery exit through anterior foramen. Finally, femoral artery and vein exit via the inferior foramen (usually called hiatus) through gap between adductor magnus)

5. Constriction of esophagus are all EXCEPT:

a) Arch of aorta

b) Left main bronchus

c) Left atrium

d) Diaphragm

Correct Answer - C

Left atrium

APPLIED ANATOMY OF OESOPHAGUS:

It is a fibro muscular tube, about 25 cm long in an adult. It extends *from the lower end of pharynx (C6) to the cardiac end of stomach (T11)*. It runs vertically but inclines to the left from its origin to thoracic inlet and again from T7 to oesophageal opening in the diaphragm. It shows three normal constrictions and it is important to know their location at oesophagoscopy. They are:

1. At pharyngo-oesophageal junction (C6) - 15 cm from the upper incisors.
2. At crossing of arch of aorta and left main bronchus (T 4) - 25 cm from upper incisors.
3. Where it pierces the diaphragm (T 10) - 40 cm from upper incisors.

6. Boundary of triangle of auscultation is not formed by?

a) Serratus anterior

b) Scapula

c) Trapezius

d) Latissimus dorsi

Correct Answer - A
Serratus anterior.

7. Axis artery of lower limb is derived from ?

a) Natal artery

b) 1st lumbar intersegmental artery

c) 5th lumbar intersegmental artery

d) Sacral artery

Correct Answer - C

Ans.C.5th lumbar intersegmental artery

Axis artery

- During fetal life (development), each limb is supplied by an axis artery that is derived from intersegmental arteries.
 - The axis artery runs along the central axis of the limb.
- Upper limb axis artery:
- Derived from: Seventh cervical intersegmental artery
 - Derivatives: Axillary artery, branchial artery, Anterior interosseous artery & Deep palmer arch
- Lower limb axis artery:
- Derived from: 5th lumbar intersegmental artery
 - Derivatives: Inferior gluteal artery, Arteria nervi ischiadici, Popliteal artery above popliteus, Lower part of peroneal artery & Some parts of plantar arch

8. Atalanto axial joint is:

a) Hinge joint

b) Ball and socket joint

c) Pivot joint

d) Saddle joint

Correct Answer - C

Pivot joint

The **atlantoaxial joint** is a **joint** in the upper part of the neck between the first and second cervical vertebrae; the atlas and axis. It is a pivot **joint**.

9. Oesophagus crosses the diaphragm at the level of:

a) T₈

b) T₁₀

c) T₁₂

d) T₂

Correct Answer - B

T₁₀

10. Tibialis posterior originates from

a) tibia

b) Fibula

c) Interosseus membrane

d) All th above

Correct Answer - D

ORIGIN:

- The tibialis posterior muscle originates on the inner posterior borders of the tibia and fibula.
- It is also attached to the interosseous membrane, which attaches to the tibia and fibula.

INSRTION:

- The tendon of the tibialis posterior muscle (sometimes called the **posterior tibial tendon**) descends posterior to the medial malleolus and terminates by dividing into plantar, main, and recurrent components.
- The main portion inserts into the tuberosity of the navicular and the plantar surface of the medial cuneiform.
- The plantar portion inserts into the bases of the second, third and fourth metatarsals, the intermediate and lateral cuneiforms and the cuboid.
- The recurrent portion inserts into the sustentaculum tali of the calcaneus.

11. Root value of Phrenic nerve is?

a) C1-3

b) C2-4

c) C3-5

d) C4-6

Correct Answer - C
C3-5

12. The following statements concerning chorda tympani nerve are true except that it?

a) Carries secretomotor fibers to submandibular gland

b) Joins lingual nerve in infratemporal fossa

c) Is a branch of facial nerve

d) Contains postganglionic parasympathetic fibers

Correct Answer - D

Chorda tympani nerve contains preganglionic parasympathetic fibers, not parasympathetic fibers. It synapses in the submandibular ganglion.

13. A patient presents with a chief complaint of chronic nose bleeds. To control the severity of these nosebleeds, his physician decides to ligate the sphenopalatine artery. From which of the following arteries does the sphenopalatine artery arise from?

a) External carotid

b) Facial

c) Maxillary

d) Ophthalmic

Correct Answer - C

The *sphenopalatine artery* is the terminal branch of the maxillary artery. The maxillary artery arises from the external carotid artery and then passes through the infratemporal fossa, giving off branches to structures in this region.

14. All of the following muscles forms the boundary of the suboccipital triangle found in the suboccipital region of the neck, EXCEPT?

a) Obliquus capitis superior muscle

b) Obliquus capitis inferior muscle

c) Rectus capitis posterior major muscle

d) Rectus capitis posterior minor muscle

Correct Answer - D

The suboccipital triangle is bounded by rectus capitis posterior major and the obliquus capitis superior and inferior muscles. The floor of this triangle is formed by the posterior occipitoatlantal membrane and the posterior arch of the C1 vertebrae.

Contents of the triangle are:

- Vertebral artery
- Suboccipital nerve
- Greater occipital nerve

15. Which of the following structure helps in maintaining the centralized location of the spinal cord in the subarachnoid space?

a) Filum terminale

b) Cerebrospinal fluid

c) Denticulate ligament

d) All of the above

Correct Answer - C

Denticulate ligaments are lateral extensions of the pia mater which attaches to the arachnoid and dura mater. *It helps in maintaining the centralized location of the spinal cord in the subarachnoid space.* These ligaments are found between the ventral and dorsal roots, and project through the arachnoid mater in order to attach to the dura mater in a series of sawtooth projections.

Filum terminale is an extension of the pia mater beyond the tip of the spinal cord which attaches to the coccyx in the vertebral canal.

16. Which of the following artery is located in the anatomical snuffbox?

a) Ulnar artery

b) Radial artery

c) Brachial artery

d) Interosseous artery

Correct Answer - B

Anatomic snuffbox is a term used to describe a triangular skin depression on the lateral side of the wrist. Radial artery can be palpated within the snuffbox as it winds around the lateral margin of the wrist to reach the dorsum of hand.

17. All of the following movements occur during abduction of shoulder, except?

a) Elevation of humerus

b) Axial rotation of clavicle

c) Medial rotation of scapula

d) Acromioclavicular joint movement

Correct Answer - C

Abduction of shoulder is associated with lateral rotation of scapula.

18. In a 24 year old man weight of the upper limb is transmitted to the axial skeleton by?

a) Coracoacromial ligament

b) Coracoclavicular ligament

c) Costoclavicular ligament

d) Coracohumeral ligament

Correct Answer - B

The axial skeleton shapes the longitudinal axis of the human body. Coracoclavicular ligament suspends the scapula from the lower one third of the clavicle and forms a strong bond between them. The weight of the upper limb is transmitted to the axial skeleton through this ligament. A fracture of the clavicle, medial to the attachment of this ligament leads to drooping of upper limb.

19. Nerve roots involved in klumpke's paralysis is?

a) C6, C7

b) C7, C8

c) C8, T1

d) T1, T2

Correct Answer - C

Klumpke's Paralysis is due to injury of the lower trunk of brachial plexus. It involves mainly the *T1 nerve root and partly C8 nerve root*. All the small muscles of the hand are paralysed. Claw hand, horner syndrome and loss of sensation on the medial aspect of the arm are the common disabilities.

20. TRUE/FALSE statements about radial nerve is/are:

1. Branch of posterior cord
2. Nerve of extensor compartment of forearm
3. Arise from C5 - T1
4. Anterior interosseous nerve is a branch of it
5. Supply skin of extensor compartment

a) 1,2,3 true & 4,5 false

b) 1,2,3,4 true & 5 false

c) 1,2,3,5 true & 4 false

d) All are true

Correct Answer - C

Radial nerve is the largest branch of the posterior cord of the brachial plexus with a root value of C5 - C8 and T1. The radial nerve is commonly injured in the region of the spiral groove. this result in the wrist drop and sensory loss over a narrow strip on the back of forearm, and on the lateral side of the dorsum of the hand.

Posterior interosseous nerve is the branch of radial nerve given off in the cubital fossa while anterior interosseous nerve is a branch of the median nerve given off in the upper part of the forearm.

Skin of the back of the forearm (i.e. extensor compartment) is supplied by the posterior cutaneous nerve of the forearm which is a branch of radial nerve.

21. An open arterial anastomosis in the shoulder occurs between the suprascapular artery and which other artery?

a) Anterior circumflex humeral

b) Circumflex scapular

c) Dorsal scapular

d) Thoracodorsal

Correct Answer - B

The circumflex scapular artery, the dorsal scapular artery, and the suprascapular artery create arterial anastomoses around the scapula. This means that the scapula will be supplied with blood even if one of these arteries is ligated. Additionally, if the subclavian or axillary artery needs to be ligated, blood can flow from the dorsal scapular artery and suprascapular artery to the circumflex scapular artery. This effectively shunts blood from the first part of the subclavian artery to the third part of the axillary artery so that the upper limb will still receive blood. The connection between the suprascapular and circumflex scapular arteries is termed an open anastomosis because it is grossly visible, compared to the anastomosis with the dorsal scapular, which typically happens within small vessels.

The *anterior circumflex humeral artery* supplies the deltoid muscle. It originates from the third part of the axillary artery and anastomoses with the posterior circumflex humeral artery. The *thoracodorsal artery* is a branch of the subscapular artery that supplies latissimus dorsi. The *transverse cervical artery* is a branch of the thyrocervical trunk that occasionally gives rise to the dorsal scapular artery. None of these arteries contribute to the scapular anastomosis.

22. Rotator cuff tear results from tear of one or more of the rotator cuff muscles and their associated tendons. Which is the most commonly injured rotator cuff muscle?

a) Supraspinatus

b) Infraspinatus

c) Teres minor

d) Subscapularis

Correct Answer - A

Supraspinatus is the most frequently injured muscle or tendon. Most of the injury result from overuse.

- **Supraspinatus muscle:** Its primary action is humeral abduction. The suprascapular nerve (C5–C6) and the suprascapular artery provide its innervation and blood supply.
- **Infraspinatus muscle:** Its primary action is lateral rotation of the humerus. The suprascapular nerve and the suprascapular artery provide its innervation and blood supply.
- **Teres minor muscle:** It causes lateral rotation of the humerus. The axillary nerve and circumflex scapular artery provide its innervation and blood supply.
- **Subscapularis muscle:** Causes medial rotation of the humerus with contraction. Upper and lower subscapular nerves and suprascapular, axillary, and subscapular arteries provide its innervation and blood supply.

23. Suprascapular artery arises from which of the following branches of subclavian artery?

a) Internal thoracic artery

b) Thyrocervical trunk

c) Costocervical trunk

d) Dorsal scapular artery

Correct Answer - B

Suprascapular artery is a branch of the thyrocervical trunk. It supplies the supraspinatus and infraspinatus muscles and the shoulder and acromioclavicular joints.

The right subclavian artery arises from the brachiocephalic trunk and left subclavian artery originates directly from the arch of aorta.

The five main branches of subclavian artery are:

- Vertebral artery
- Internal mammary (thoracic) artery
- Thyrocervical trunk
- Costocervical trunk
- Dorsal scapular artery

24. Which of the following structure is NOT a content of the cubital fossa?

a) Brachial artery

b) Ulnar nerve

c) Radial nerve

d) Median nerve

Correct Answer - B

The *cubital fossa* is a triangular intermuscular space seen as a shallow surface depression in front of the elbow. The contents of the cubital fossa are tendon of biceps brachii, brachial artery, median nerve and radial nerve. Radial nerve is present in the superolateral aspect of the fossa under cover of brachioradialis.

Boundaries of cubital fossa:

- *Base* is formed by an imaginary line passing through the medial and lateral epicondyle of humerus.
- *Medial boundary* is formed by lateral margin of pronator teres muscle.
- *Lateral boundary* is formed by medial margin of brachioradialis muscle.
- *Apex* is located at the crossing of pronator teres and brachioradialis muscle.
- *Floor* consist of brachialis in the upper part and supinator in the lower part.

25. Common peroneal nerve is related to which of the following structures?

a) Shaft of tibia

b) Neck of fibula

c) Lower tibio-fibular joint

d) Shaft of fibula

Correct Answer - B

The common fibular nerve arises from the posterior division of the sacral plexus (L4–S2) and descends in an inferolateral direction, across the popliteal fossa to the fibular head. Just distal to the fibular head, the common fibular nerve bifurcates into the deep fibular and superficial fibular nerves. *It is easily palpated against the neck of fibula because of its subcutaneous position. It is commonly injured in fractures of neck of the fibula. It gets thickened in leprosy which may also cause foot drop.*

26. The muscle that acts primarily as an evertor of ankle inserted into the medial cuneiform is which of the following?

a) Peroneus longus

b) Peroneus brevis

c) Tibialis anterior

d) Tibialis posterior

Correct Answer - A

The peroneus longus and brevis act primarily as evertors, with the peroneus brevis being the stronger of the two. In the question, the evertor inserted to the medial cuneiform, which is peroneus longus.

The peroneus brevis inserts on the base of the fifth metatarsal and the peroneus longus courses under the cuboid to insert on the base of the first metatarsal and medial cuneiform.

The tibialis anterior is the dorsiflexor of foot at the ankle joint. It is the invertor of the foot at the midtarsal and subtalar joints.

Tibialis posterior is the principal invertor of the foot.

27. Among the following muscles, the one that is found in the first layer of the sole is?

a) Adductor hallucis

b) Flexor digitorum brevis

c) Flexor digiti minimi brevis

d) Flexor hallucis longus

Correct Answer - B

Flexor digitorum brevis, abductor hallucis and abductor digiti minimi belong to first layer of the sole. Flexor digitorum brevis lies beneath the aponeurosis, medial to it lies abductor hallucis and lateral to it lies abductor digiti minimi.

- Tendons of flexor hallucis longus, and of flexor digitorum longus, flexor digitorum accessorius, and the lumbricals forms the *second layer of the sole*.
- *Muscles which form the third layer* are flexor hallucis brevis, flexor digiti minimi brevis, and abductor hallucis.
- *Muscles forming the fourth layer of sole* are tendon of tibialis posterior, tendon of peroneus longus and interosseous muscles and long plantar ligament.

28. In the lungs bronchial arteries supply:

a) Till tertiary bronchi

b) Till segmental bronchi

c) Till respiratory bronchioles

d) Till alveolar sacs

Correct Answer - C

Bronchial arteries are branches of the descending thoracic aorta. They supply the bronchial wall as far as the respiratory bronchioles.

29. All veins opens into coronary sinus, EXCEPT?

a) Great cardiac vein

b) Anterior cardiac vein

c) Middle cardiac vein

d) Left posterior ventricular vein

Correct Answer - B

The coronary sinus drains all the venous blood of the heart, except those carried by anterior cardiac veins and venae cordis minimae. Anterior cardiac veins opens into the right atrium, to the left of the opening of inferior vena cava. Venae cordis minimae drain directly into the chambers of the heart.

The coronary sinus receives the following veins: (1) the great cardiac vein; (2) the small cardiac vein; (3) the middle cardiac vein; (4) the posterior vein of the left ventricle; and (5) the oblique vein of the left atrium.

30. Which chamber's anterior wall forms most of the sternocostal surface of the heart?

a) Left atrium

b) Left ventricle

c) Right atrium

d) Right ventricle

Correct Answer - D

The heart has three important surfaces: an anterior surface, a diaphragmatic surface, and a pulmonary surface. The anterior surface, or sternocostal surface, is mostly made up of the right ventricle. The diaphragmatic surface is mostly the left ventricle, but a little bit of the right ventricle sits on the diaphragm as well. Finally, the pulmonary surface, which is on the left, is mostly made up of the left ventricle.

31. The key to the root of the neck is the scalenus anterior muscle. Which among the following is TRUE about scalenus anterior?

a) Not Pierced by phrenic nerve

b) Attached to scalene tubercle on 2nd rib

c) Separates subclavian artery from subclavian vein

d) Pierced by phrenic nerve

Correct Answer - B

- The *subclavian vein* forms an arch across the pleura at a level below the arch of subclavian artery. The two arches are separated from each other by scalenus anterior muscle.
- *Scalenus anterior* arises from the anterior tubercles of C3-C6 and attaches to the scalene tubercle and adjacent ridge on the inner border and upper surface of the first rib.
- *Phrenic nerve* passes vertically down across the obliquity of the muscle, plastered there to by the prevertebral fascia.
- *Transcervical and suprascapular arteries* lie between the scalenus anterior and the carotid sheath.

32. Torus aorticus is an impression in the cavity of?

a) Right atrium

b) Left atrium

c) Right ventricle

d) Left ventricle

Correct Answer - A

Torus aorticus is a bulge in the right atrial wall anterosuperiorly above the membranous septum. It is superior to the coronary sinus and anterior to the fossa ovalis. It represents the deeper and anterior surface of the posterior sinus and cusp of the aortic valve.

33. What is the root value of long thoracic nerve?

a) C3 4 5

b) C5 6 7

c) C7 8 T1

d) C2 3 4

Correct Answer - B

Long thoracic nerve (C5–C7): It branches off the C5–C7 roots, descends posteriorly to the roots of the plexus and the axillary artery and along the lateral surface of the serratus anterior muscle, with the lateral thoracic artery, while supplying the muscle. The long thoracic nerve is one of the few nerves found superficial to the serratus anterior muscle.

Phrenic nerve (C3–C5): Courses vertically along the anterior scalene muscle between the subclavian artery and the subclavian vein en route to innervate the diaphragm. ("C3–C5, keep the diaphragm alive" is a mnemonic that is used to remember the spinal nerve levels of the phrenic nerve.)

Transverse cervical nerve (C2–C3): Innervates the skin over the anterior part of the neck.

Supraclavicular nerve (C3–C4): Innervates the skin over the lower portion of the neck, upper part of the chest, and the shoulder.

Also Know:

- *Erb's palsy (brachial plexus birth injury)* is caused by a stretch injury of the brachial plexus that occurs during a difficult birth, specifically to nerve roots C5 and C6 and sometimes C7.
- *Klumpke's palsy* results from injury to the inferior trunk of the brachial plexus. The intrinsic muscles of the hand are affected and a "claw hand" may result.

34. Lymph nodes draining the breast and lying behind the pectoralis minor are labelled as:

a) Level 1

b) Level 2

c) Level 3

d) None of the above

Correct Answer - B

Axillary nodes receive more than 75% of the lymph from the breast. There are 20-40 nodes, grouped artificially as pectoral (anterior), subscapular (posterior), central and apical. Surgically, the nodes are described in relation to pectoralis minor. Those lying below pectoralis minor are the low nodes (**level 1**), those behind the muscle are the middle group (**level 2**), while the nodes between the upper border of pectoralis minor and the lower border of the clavicle are the upper or apical nodes (**level 3**).

35. Most common diaphragmatic hernia is:

a) Bochdalek hernia

b) Morgagni hernia

c) Paraesophageal hernia

d) None of the above

Correct Answer - A

Diaphragmatic hernias are of various types. The most common is a posterolateral (Bochdalek) hernia, which occurs as a result of a defect in the posterior diaphragm in the region of the tenth or eleventh ribs.

36. Which among the following is the last tributary of the azygos vein?

a) Right-superior intercostal vein

b) Hemi-azygos vein

c) Right bronchial vein

d) Accessory azygos vein

Correct Answer - C

Azygos vein receives venous drainage from the right bronchial vein near its termination.

Tributaries of the azygos vein include:

- The right superior intercostal vein (a single vessel formed by the second, third, and fourth intercostal veins)
- Fifth to eleventh right posterior intercostal veins
- The hemiazygos vein
- The accessory hemiazygos vein
- Esophageal veins
- Mediastinal veins
- Pericardial veins
- *Right bronchial veins*

37. What is the root value of phrenic nerve?

a) C1-3

b) C2-4

c) C3-5

d) C4-6

Correct Answer - C

The cervical plexus also gives rise to the phrenic nerve (C3–C5). Courses vertically along the anterior scalene muscle between the subclavian artery and the subclavian vein en route to innervate the diaphragm.

Also know:

- "C3–C5, keep the diaphragm alive" is a mnemonic that is used to remember the spinal nerve levels of the phrenic nerve.

38. Structures passing through lesser sciatic foramen are all, except:

a) Pudendal nerve

b) Internal pudendal artery

c) Nerve to obturator externus

d) Tendon of obturator internus

Correct Answer - C

Structures passing through lesser sciatic foramen are **tendon of obturator internus muscle, nerve to obturator internus, pudendal nerve, internal pudendal artery and vein.**

Structures passing through greater sciatic foramen are:

- Piriformis
- Sciatic nerve
- Posterior cutaneous nerve of thigh
- Superior and inferior gluteal nerve
- Nerve to obturator internus and quadratus femoris
- Pudendal nerve
- Superior and inferior gluteal nerves and arteries
- Internal pudendal artery and vein

39. All of the structures are included in the 'Triangle of Calot' are all, EXCEPT:

a) Portal vein

b) Cystic artery

c) Right hepatic artery

d) Lymph node of Lund

Correct Answer - A

The triangle of Calot is an important landmark whose boundaries include the common hepatic duct medially, the cystic duct laterally, and the inferior edge of the liver superiorly. **The cystic lymph node** of Lund (also known as the Calot node) is within this triangle; also here, the **cystic artery** branches off the right hepatic artery. The Calot node is the main route of lymphatic drainage of the gallbladder.

40. The kidney have the following anatomic characteristics, **EXCEPT**:

a) The right kidney relates anteriorly to the liver

b) The left kidney relates anteriorly to the pancreas

c) The kidneys lie completely within the retroperitoneal space

d) The right renal artery arises from the aorta passing anterior to the vena cava and enters the kidney at the hilus

Correct Answer - D

The kidneys lie along the vertebral column lying against the psoas major muscle extending from the first to the fourth lumbar vertebrae. They lie exclusively within the retroperitoneal space. The renal arteries arise from the aorta. The right renal artery passes behind the inferior vena cava, entering the kidney at the hilus where it divides into segmental branches. The five segmental branches give rise to the interlobar arteries, which in turn give rise to the arcuate arteries. The interlobar arteries arise from the arcuate and give off the afferent arterioles to the glomerulus.

41. Which of the following is the most medial in the femoral triangle?

a) Lymphatics

b) Nerve

c) Artery

d) Vein

Correct Answer - A

The femoral triangle is an area in the inguinal region that is shaped like an upside-down triangle and is bordered by the sartorius muscle, adductor longus muscle and inguinal ligament. *The femoral triangle contains the following structures from lateral to medial:*

- *Femoral nerve.* Originates as a branch of the lumbar plexus. The femoral nerve is not contained within the femoral sheath.
- *Femoral artery.* Continuation of the external iliac artery. The femoral artery is located midway between the anterior superior iliac spine and the pubic symphysis.
- *Femoral vein.* Continues as the external iliac vein.
- *Lymphatics*
The inferior portion of the femoral triangle communicates with a facial canal (adductor canal) that runs deep to the sartorius muscle.

42. All of the following structures pass through the greater sciatic foramen, EXCEPT?

a) Piriformis muscle

b) Pudendal nerve

c) Inferior gluteal vessel

d) Internal pudendal vessel

Correct Answer - B

Pudendal nerve courses through the lesser sciatic foramen.

Structures passing through the lesser sciatic foramen are:

- Pudendal nerve
- Internal pudendal vessels
- Obturator internus tendon

Structures passing through the greater sciatic foramen are:

- Sciatic nerve
- Piriformis muscle
- Internal pudendal and inferior gluteal vessels
- Other branches of the sacral nerve plexus

43. All of the following structures passes through lesser sciatic foramen, EXCEPT ?

a) Inferior gluteal vessels

b) Internal pudendal vessels

c) Pudendal nerve

d) Nerve to obturator internus

Correct Answer - A

Structures passing through the lesser sciatic foramen are tendon of obturator internus, internal pudendal vessels and pudendal nerve.

Structures passing through greater sciatic foramen are:

- Piriformis muscle
- **Superior and inferior gluteal vessel**
- Internal pudendal vessel
- Pudendal nerve
- Sciatic nerve
- Posterior femoral cutaneous nerve
- Nerve to obturator internus
- Quadratus femoris

Structures passing through both greater and lesser sciatic foramen:

- Pudendal nerve
- Internal pudendal vessels
- Nerve to obturator internus

44. All of the following cranial nerves contain Somatic Efferents, except?

a) VII Nerve (Facial nerve)

b) III Nerve (Oculomotor nerve)

c) IV Nerve (Trochlear nerve)

d) VI Nerve (Abducent nerve)

Correct Answer - A

Facial nerve does not contain Somatic Efferents.

45. TRUE about corpus callosum is/are?

1. Largest commissure of the brain
2. Connect two frontal lobe
3. Unite two hemispheres
4. Superiorly related to indusium griseum
5. Co-ordinates activities of two hemispheres

a) 1,2,3 & 5

b) 1,2,3 & 4

c) 2,3,4 & 5

d) 1,2,3,4 & 5

Correct Answer - D

Corpus callosum is the largest commissure of the brain. It connects the two cerebral hemispheres. It connects all part of the cerebral cortex of the two sides, except the lower and anterior parts of the temporal lobes which are connected by the anterior commissures.

- It is approximately 10 cm long, with an anterior end approximately 4 cm from the frontal lobes and posterior end approximately 6 cm from the occipital lobe.
- The superior surface of callosal trunk is covered by a thin layer of grey matter, the indusium griseum.
- Connection that link the same, or similar area on each side are termed homotopic connections. The corpus callosum also interconnects heterogeneous cortical areas on the two sides (heterogenous connections).

Fibres of corpus callosum

1. The rostrum connects the orbital surfaces of the two frontal lobes.
2. The forceps minor is made up fibres of genu that connects the two frontal lobes.
3. The forceps major is made up of fibres of the splenium connecting the occipital lobes tapetum.

Functional significance:

The corpus callosum helps in co-ordinating activities of the two hemispheres.

46. Parathyroid gland develops from ?

a) Branchial cyst

b) Branchial cleft

c) Branchial pouch

d) Branchial arch

Correct Answer - C

Parathyroid gland develops from 3rd and 4th branchial or pharyngeal pouches.

Superior parathyroid develop from the 4th pharyngeal pouch and inferior parathyroid develop from the 3rd pharyngeal pouch.

Ref: Langman's medical Embryology, 9th Edition, Page 384.

47. A newborn baby is noted to have a left unilateral cleft lip. There are no abnormalities of the baby's palate. Which of the following developmental defects accounts for this occurrence?

a) Failure of the left lateral palatine process to fuse with the median palatine process

b) Failure of the left maxillary prominence to unite with the left medial nasal prominence

c) Failure of the primary palate to fuse with the secondary palate

d) Failure of the right and left medial nasal prominences to merge

Correct Answer - B

In the formation of the upper lip, the right and left medial nasal prominences merge to form the philtrum of the upper lip. The lateral maxillary prominence then merges with the merged medial nasal prominences. Failure of this merger to occur results in a **unilateral cleft lip**. Failure of a lateral palatine process to fuse with the median palatine process, which is synonymous with a failure of the primary palate to fuse with the secondary palate, results in a **primary cleft palate**. Primary clefts of the palate are found anterior to the incisive foramen of the palate. Primary cleft palates may occur along with cleft lips but are the result of a separate developmental defect.

Failure of the right and left medial nasal prominences to merge results in a **median cleft lip**. This is a rare anomaly. Normally, the right and left medial nasal prominences merge into a single prominence which forms the philtrum of the lip.

Ref: Losee J.E., Gimbel M., Rubin J., Wallace C.G., Wei F. (2010). Chapter 45. Plastic and Reconstructive Surgery. In F.C. Brunickardi, D.K. Andersen, T.R. Billiar, D.L. Dunn, J.G. Hunter, J.B. Matthews, R.E. Pollock (Eds), *Schwartz's Principles of Surgery*, 9e.

48. Ameloblasts produce:

a) Cementum

b) Dentin

c) Enamel

d) None of the above

Correct Answer - C

In the meantime, epithelial cells of the inner dental epithelium differentiate into ameloblasts (enamel formers). These cells produce long enamel prisms that are deposited over the dentin

- Ameloblasts form enamel (the hardest component of teeth) and are derived from surface ectoderm.
- Odontoblasts form dentine and are derived from neuroectoderm (from neural crest).

49. Intervertebral disc is an example of which category of cartilages?

a) Hyaline cartilage

b) Fibro cartilage

c) Elastic cartilage

d) Fibroelastic cartilage

Correct Answer - B

Intervertebral disc is a type of fibrocartilage. Fibrocartilage is characterized by large amount of irregular and dense bundles of collagen fibers in the matrix. It consists of alternating layers of cartilage matrix and thick dense layers of type I collagen fibers.

50. Pericytes, which are seen in the capillary bed are:

a) Modified endothelial cells

b) Phagocytes

c) Pluripotent cells lining the capillaries

d) None of the above

Correct Answer - C

Pericytes are closely associated with capillaries. It is most commonly found at the venous end of capillary bed, and also extend onto the post capillary venules. They can differentiate into smooth muscle cells during blood vessel growth and during repair after injury to a vessel. They also act as contractile cells and can affect blood flow through the capillary.

Pericytes have histologic characteristics of both smooth muscle cells and endothelial cells.

51. Which of the following type of cell is involved in myelination of the CNS?

a) Microglia

b) Astrocytes

c) Macrophages

d) Oligodendrocytes

Correct Answer - D

Oligodendroglial cells are a type of neuroglial cells, they myelinate the nerve fibre of the central nervous system.

The formation of a myelin sheath is the result of a process from an oligodendrocyte spiralling around an axon so that the cytoplasm is extruded until the opposite membranes meet, thus forming a multi-layered lipoprotein coat with a node of Ranvier at each end.

It has multiple cytoplasmic processes and myelinate several axons at the same time.

Myelination of the cortex begins at 7-8 mo gestation and continues into adolescence and young adulthood. It proceeds in a posterior to anterior fashion, allowing progressive maturation of sensory, motor, and finally associative pathways.

Must know:

- **Peripheral nerves are myelinated from the schwann cells.** Loss of myelin, known as demyelination, results in disturbance of the ability to transmit a nerve impulse through the demyelinated segment and this has serious consequences for function.
- Damage to one oligodendrocyte, therefore, can result in loss of myelin from many axons, whereas damage to a Schwann cell only results in loss of myelin from a single axon.

Good to know:

- Tracts in the nervous system get myelinated at about the time they

start to function.

52. Ito cells are found in:

a) Brain

b) Kidney

c) Liver

d) Lung

Correct Answer - C

Hepatic stellate cells are also known as perisinusoidal lipocytes or Ito cells and are much less numerous than hepatocytes. They play a major role in pathological processes. In response to liver damage, they become activated and predominantly myofibroblast-like. They are responsible for the replacement of toxically damaged hepatocytes with collagenous scar tissue - hepatic fibrosis, seen initially in zone 3, around central veins. This can progress to cirrhosis, where the parenchymal architecture and pattern of blood flow are destroyed, with major systemic consequences.

53. The epiphysis at the tip of coracoid process is an example of which of the following type of epiphysis?

a) Traction

b) Atavistic

c) Pressure

d) A or C

Correct Answer - B

Coracoid process is shaped like a bent finger. It is an example of atavistic epiphysis. Atavistic epiphysis are formed by centers of ossification which are considered to represent the skeletal elements which were separated in some earlier evolutionary phases but later found to remain fused with adjacent bones.

Other types of epiphysis are:

- **Pressure epiphysis:** It helps in transmitting body weight and also protects epiphyseal cartilage. eg. head of femur and head of humerus
- **Traction epiphysis:** It is caused by pull of muscle. eg: trochanter of femur, tuberosities of humerus.
- **Aberrant epiphysis:** Presence of an occasional separate epiphysis in a bone. eg. In the first metacarpal, normal epiphysis is seen at the base, but it may have another one at the head.

54. Relation of caudate lobe of liver is :

a) Posterior to portal vein

b) Anterior to right inferior phrenic artery

c) Posterior to ligamentum teres

d) Posterior to ligamentum venosum

Correct Answer - B

B. i.e. Anterior to right inferior phrenic artery

55. All are Anterior relations of the Right kidney *except*:

a) Suprarenal gland

b) Hepatic flexure of the colon

c) Third part of the duodenum

d) Liver

Correct Answer - C

C i.e. Third part of duodenum

- The upper pole of the kidney is covered by the suprarenal gland.
- Anteriorly, the right kidney is related to the liver, duodenum, ascending colon or right colic flexure, and small intestine.
- The left is related to the spleen, stomach, pancreas, descending colon or left colic flexure, and small intestine.
- Posteriorly, the kidneys are related to rib 12 and the diaphragm, psoas major, quadratus lumborum, and transversus abdominis.
- The upper part of the kidney is usually separated by the diaphragm from the pleura and lung.
- In the vertebrocostal trigone, however, the kidney and pleura may be separated only by connective tissue

56. Lesser sac of stomach is bounded by:

a) Posterior wall of stomach

b) Visceral surface of spleen

c) Under surface of liver

d) All

Correct Answer - A

A. i.e. Posterior wall of stomach

- Lesser sac/ Omental bursa is bounded anteriorly by *stomach, caudate lobe of liver, lesser omentum & greater omentum (ant. 2 layers)*; and posteriorly by structures forming *stomach bed (i.e. diaphragm, pancreas, spleen etc) & greater omentum (posterior 2 layers)*

Lesser sac or omental bursa is the *site for abscess formation in posterior perforation of gastric ulcer and internal hernia through epiploic foramen*

57. Which of the following about the valves of Houston is true?

a) They disappear after mobilization of the rectum

b) The middle valve folds towards the right side

c) The upper valve corresponds to the anterior peritoneal reflection

d) The valves contain all layers of the muscle wall

Correct Answer - A

A i.e. They disappear after mobilization of rectum

58. All are component of urogenital diaphragm except :

a) Left transverse perenii profundus

b) Right transverse perenii profundus

c) Sphincter Urethrae

d) Transverse perenii superficialis

Correct Answer - D

D i.e. Transverse perenii superficialis

- Superficial perineal muscles *include bulbospongiosus, ischiocavernosus & superficial transverse perinei*

- Perineal body is formed by *superficial & deep transverse perini, levator ani, bulbospongiosus, sphincter urethrae & external anal sphincter.*

Superficial transverse perinii muscle is a part of perineal body & is cut in episiotomy but is not a part of urogenital diaphragm, which is formed by deep transverse perinii, sphincter urethrae and perineal membrane

59. Paramesonephric duct forms which of the following

a) Ureter

b) Uterus

c) Bladder

d) Penis

Correct Answer - B

B. i.e. Uterus

Paramesonephric ducts (or **Müllerian ducts**) are paired ducts of the embryo that run down the lateral sides of the urogenital ridge and terminate at the sinus tubercle in the primitive urogenital sinus. In the female, they will develop to form the uterine tubes, uterus, cervix, and the upper two third of the vagina. Lower 1/3 of vagina is derived from sinovaginal bulb derived from urogenital sinus; in the male, they are lost. These ducts are made of tissue of mesodermal origin.

60. Superficial inguinal lymph node drains

A/E:

a) Toes & finger

b) Perineum

c) Gluteal region

d) Anterior abdominal wall below umbilicus

Correct Answer - A
A i.e. Toes & fingers

61. Which of the following is wrong regarding ophthalmic artery

- a) Present in dura along with optic nerve
- b) Supplies anterior ethmoidal sinus
- c) Artery to retina is end artery
- d) Leaves orbit through inferior orbital fissure

Correct Answer - D

Ans. is 'd' i.e., Leaves orbit through inferior orbital fissure [*Ref BDC 6thle Vol.3 p. 209*]

- Ophthalmic artery does not leave the orbit. It terminates near the medial angle of eye by dividing into supratrochlear and dorsal nasal branches.
- It lies along with optic nerve in a common dural sheath.
- It supplies anterior ethmoidal sinus by its anterior ethmoidal branch.
- Central artery to retina (branch of ophthalmic artery) is an end artery.

62. All of the following are branches of subclavian artery except :

a) Vertebral artery

b) Thyrocervical trunk

c) Subscapular artery

d) Internal thoracic artery

Correct Answer - C

C i.e. Subscapular artery

Subscapular artery is the *largest branch of 3rd part of axillary artery* ; vertebral artery is the first & largest branch of 1st part of *subclavian artery*.

63. Ovarian artery is a branch of :

a) Abdominal aorta

b) Anterior iliac artery

c) Common iliac artery

d) Posterior iliac artery

Correct Answer - A
A. i.e. Abdominal aorta

64. Which is the direct branch of celiac trunk:

a) Rt. Gastric

b) Lt. Gastric

c) Gastroduodenal

d) Rt gastro epiploic artery

Correct Answer - B
Ans. B. i.e. Lt. Gastric

65. Which of the following arteries gives blood supply to the ductus deferens?

a) Cremastric artery

b) Inferior epigastric artery

c) Middle rectal artery

d) Superior vesical artery

Correct Answer - D

D i.e. Superior vesicle artery

Vas (ductus) deferens is 45 cm long muscular tube which conveys sperms from epididymis to ejaculatory duct. It receives blood from its own artery (i.e., artery to ductus deferens) which usually arises from superior vesical artery (but may occasionally arise from inferior vesical artery). Artery to ductus deferens anastomose with testicular artery to supply epididymis and testis.

- In treating varicocele, both testicular artery & vein are ligated quite high up, which provides the advantage of ligating venae comitantes of artery. If left open these venae comitantes can lead to recurrence because of their anastomoses with internal spermatic veins

66.

Which of this part of vertebral canal will show secondary curves with concavity backwards?

a) Cervical

b) Thoracic

c) Sacral

d) Coccyx

Correct Answer - A

A i.e. Cervical

The thoracic and sacral kyphotic curves are termed **primary curves**, because they are present in the fetus.

The cervical and lumbar curves are *compensatory* or **secondary**, and are developed after birth.

KYPHOTIC CURVE:

- The thoracic curve, concave forward, begins at the middle of the second and ends at the middle of the twelfth thoracic vertebra. Its most prominent point behind corresponds to the spinous process of the seventh thoracic vertebra. This curve is known as a kyphotic curve.
- The sacral curve begins at the sacrovertebral articulation, and ends at the point of the coccyx; its concavity is directed downward and forward as a kyphotic curve.

LORDOTIC CURVES:

- The lumbar curve is more marked in the female than in the male; it begins at the middle of the last thoracic vertebra, and ends at the sacrovertebral angle. It is convex anteriorly, the convexity of the lower three vertebrae being much greater than that of the upper two. This curve is described as a lordotic curve.
- The upper cervical spine has a curve, convex forward, that begins at

the axis (second cervical vertebra) at the apex of the odontoid process or dens, and ends at the middle of the second thoracic vertebra; it is the least marked of all the curves. This inward curve is known as a lordotic curve.



67. True regarding cavity of diencephalons is

- a) Septum pellucidum forms partition
- b) Septum pellucidum cavity opens superiorly
- c) Lateral wall is lamina terminalis
- d) Inter thalamic adhesions join lateral walls

Correct Answer - D

D i.e. Inter thalamic adhesions join lateral Walls

- Lamina terminalis is a thin sheet of gray matter, which *extend between two hemisphere from rostrum of corpus callosum to top of optic chiasma forming the anterior wall of 3rd ventricle.*
- Septum pellucidum is a thin vertical sheet of (gray & white) nervous tissue, which connects *corpus callosum (rostrum, genu & front of body) to anterior column of fornix and forms partition between anterior horns of lateral ventricles (not 3rd ventricle or cavity of diencephalon).*
- Lateral wall of cavity of diencephalon (3rd ventricle) is formed by thalamus, hypothalamus, hypothalamic sulcus & subthalamus.

68. Blood Brain Barrier is/are formed by:

a) Oligodendrocytes

b) Microglial cell

c) Astrocytes

d) Schwann cell

Correct Answer - C
C i.e. Astrocytes; E i.e. Neuroglia

69. All of the following cranial nerves contain Somatic Efferents, Except:

a) VII Nerve (Facial nerve)

b) III Nerve (Oculomotor nerve)

c) IV Nerve (Trochlear nerve)

d) VI Nerve (Abducent nerve)

Correct Answer - A
A i.e. VII Nerve (Facial nerve)

70. The longest cranial nerve :

a) Optic

b) Abducent

c) Trigeminal

d) vagus

Correct Answer - D

D i.e., vagus

- **Vagus** (Xth) Cranial nerve has the longest and varied area of supply.
- The trigeminal (V, fifth) is the largest & thickest cranial nerve.
- The **trochlear nerve** is the smallest nerve in terms of the number of axons it contains.
- The **trochlear nerve has the greatest intracranial length.**
- The **olfactory nerve** is the shortest of the twelve cranial nerves
- **Abducent nerve** has the longest **intra-cranial INTRADURAL** course

71. Meiosis in spermatogenesis occurs in which of the following step?

a) Primary spermatocyte to intermediate spermatocyte

b) Primary spermatocyte to secondary spermatocyte

c) Secondary spermatocyte to round spermatid

d) Round spermatid to elongated spermatid

Correct Answer - B

B i.e. Primary spermatocyte to secondary spermatocyte

72. Blastocyst implantation close to internal os causes

a) Placenta previa

b) Placenta percreta

c) Placenta increta

d) Abruptio Placenta

Correct Answer - A

A i.e. Placenta previa

- When the placenta is implanted partially or completely over the lower uterine segment, over and adjacent to the internal os, it is called placenta previa

73. Somites develop from-

a) Notochord

b) Intermediate mesoderm

c) Paraxial mesoderm

d) Lateral plate mesoderm

Correct Answer - C

C i.e. Paraxial mesoderm

Paraxial mesoderm form *somitomeres* which give rise to *Somites* (*metamers* or *primitive segments*)

Intra-embryonic mesoderm is formed by proliferation of cells in *primitive streak*. & it separates ectoderm & endoderm except in these region - Prochordal plate

- Cloacal membrane

Caudal to prochordal plate in midline as this place is occupied by notochord.

74. Muscular component of dorsal aorta develops from?

a) Axial mesoderm

b) Paraxial mesoderm

c) Intermediate mesoderm

d) Lateral plate mesoderm

Correct Answer - D

D i.e. Lateral plate mesoderm

Muscular component of dorsal aorta develops from splanchnopleure (splanchnic/ visceral) layer of lateral plate mesoderm

- Angioblastic mesenchyme forms early in 3rd week of development from extraembryonic mesenchyme in the splanchnopleure (splanchnic/ visceral) of yolk sac, in the body stalk (containing allantois), and in the somatopleure of the chorion. The *peripheral cells* flattens as a *vacular endothelium*, whereas *central cells* transform into *primitive RBCs*.
- *Intra embryonic blood vessels are first seen at endoderm mesenchyme interface within the lateral splanchnic mesenchyme* at the caudolateral margins of the cranial intestinal portion. Angioblastic competence has been demonstrated within the ventral (splanchnopleuric) mesenchyme with which the endoderm interacts. However, the notochord, prechordal plate and ectodermal tissue do not contain angiogenic cells.
- The earliest angiogenic mesenchymal cells form blood vessels by vasculogenesis, a process in which new vessels (*e.g endothelial heart tubes, dorsal aortae, umbilical and early vitelline vessels*) develop in situ. Later vessels develop by angiogenesis, sprouting and branching from the endothelium of pre existing vessels.

- Somites , derived from paraxial mesenchyme, have been shown to be a source of angioblasts which either differentiate with the somite derivatives or migrate to the neural tube, ventrolateral body wall, limb buds, mesonephros and dorsal > part of aorta.

75. During first 3-4 month of gestation erythrocytes are formed by

a) Yolk sac

b) Liver

c) Spleen

d) All

Correct Answer - D

A i.e. Yolk sac; B i.e. Liver; C i.e. Spleen

Erythropoiesis (blood production) occurs in mesodermal wall of yolk sac(i.e. intravascular) from 3 weeks to 3 months of gestation and in liver > spleen & lymph nodes(hepatic extramedullary) from 2 months to 7 months of gestation. After this erythropoiesis occurs in marrow (myeloid tissue).

76. All of the following are derived from pharyngeal arches except:

a) Tensor Tympani

b) Palatine Tonsils

c) Mylohyoid

d) Tensor veli Palatini

Correct Answer - B

Ans. B i.e. Palatine Tonsils

- Tensor tympani, tensor veli palatine (i.e. palatine tensor) & mylohyoid develop from 1st (mandibular pharyngeal arch; orbicularis oculi & orbicularis oris develop from 2nd (hyoid)) pharyngeal or branchial arch. Whereas, levator palpebrae superioris is a somatic muscle that develops from prochordal mesenchyme
- Palatine tonsils and tonsillar fossa are derived from (2nd) pharyngeal pouch and not from pharyngeal arches

77. Superior parathyroid glands are derived from :

a) 1st branchial pouch

b) 3rd branchial pouch

c) 4th branchial pouch

d) 5th branchial pouch

Correct Answer - C
C i.e. 4th branchial pouch

78. Third ventricle is derived from

a) Mesencephalon

b) Rhombencephalon

c) Thalamencephalon

d) Telencephalon

Correct Answer - C

C i.e. Thalamencephalon

- The part of the diencephalon of the brain that includes the thalamus, pineal gland, and adjacent structures
 - **Thalamencephalon** also called **thalamic region** is a complex structure comprising thalamus (in the wider sense of the term *thalamus*, i.e. dorsal thalamus, or thalamus proper, plus subthalamus, or ventral thalamus) and several adjacent structures: epithalamus and metathalamus
- DEVELOPMENT:
- The cavity of the thalamencephalon opens behind into the cavity of the middle cerebral vesicle, and in front communicates with the hollow rudiments of the cerebral hemispheres, and eventually it becomes the cavity of the third ventricle.
 - The floor of the thalamencephalon is ultimately developed into the optic chiasma, part of the optic nerves, and the infundibulum.
 - The latter comes in contact with a process from the mouth, uniting with which it ultimately forms the pituitary body.
 - From the posterior part of the roof of the thalamencephalon is developed the pineal gland .
 - The anterior part of the roof of the thalamencephalon becomes very thin, and its place is finally occupied by a thin membrane containing a vascular plexus, which persists in the roof of the third ventricle

{choroidplexus).

- From the sides of the thalamencephalon, which become extremely thickened, are developed the optic thalami.

79. Diaphragm develops from all except:

a) Septum transversum

b) Dorsal mesocardium

c) Pleuroperitoneal membrane

d) Cervical myotomes

Correct Answer - B

B i.e. Dorsal mesocardium

- Diaphragm develops **from 4 structures** derived from **mesoderm** which unite to form a sheet.

1) Septum transversum :- Gives origin to sternal part and central tendinous region.

2) Pleuroperitoneal membrane :- Dorsal paired portion.

3) Dorsal mesentery of oesophagus :- Gives origin to crural part (Dorsal unpaired portion).

4) Lateral body walls (from cervical myotome) :- Gives origin to peripheral costal portion of diaphragm.

Mn - "ST PM DMO and CM = ST Prime Minister, District Medical Officer & Chief Minister"

80. Ventral mesogastrium gives rise to

a) Lesser omentum

b) Greater omentum

c) Falciform ligament

d) a & c

Correct Answer - D

A. i.e. Lesser omentum; C i.e. Falciform ligament

Ventral mesogastrium gives rise to Lesser omentum; *Falciform, Coronary & Triangular ligaments*Q. Mn "Lesser FACT"

81. Lymphatic drainage of cervix is to

a) Iliac lymph nodes

b) Para aortic lymph nodes

c) Superficial inguinal lymph nodes

d) Deep inguinal lymph nodes

Correct Answer - A
A. i.e. Iliac lymph nodes

82. The thoracic duct crosses from the right to the left at the level of

a) T12 vertebra

b) T 6 vertebra

c) T5 vertebra

d) T2 vertebra

Correct Answer - C

C i.e. T5 vertebrae

Thoracic duct begins as continuation of the upper end of the cisterna chyli near the lower border of T12 vertebra and enters the thorax through the aortic opening of diaphragm (at T12).

It then ascends through the posterior mediastinum and at T5 level crosses from right side to the left side and ascends along left margin of oesophagus to enter the neck

83. Anterior cruciate ligament prevents :

a) Anterior dislocation of tibia

b) Posterior dislocation of tibia

c) Anterior dislocation of femur

d) Posterior dislocation of femur

Correct Answer - A

A i.e. Anterior dislocation of tibia

84. Parietal peritonium is lined by ?

a) Simple squamous

b) Stratified squamous

c) Cuboidal

d) Columnar

Correct Answer - A

A i.e. Simple squamous

- Transitional epithelium is a multilayered (4 - 6) stretchable epithelium, which has *extra reserve of cell layers* i.e. as tension increases the epithelial sheet is expanded & number of observable cell layers decrease & cell shape change from cuboid to squamous.
- The deepest layer of transitional epithelium is *columnar or cuboidal*; middle layer is *polyhedral or pear shaped* & surface layer is *umbrella shaped*.
- It differs from stratified squamous epithelium in that the cells at surface are not squamous.
- *Membranous and most of penile urethra* (in males) is lined by pseudostratified or *stratified columnar epithelium*
Ansa nephroni (renal loop of Henle) and mesothelium (i.e. serous/outer/parietal layer of peritoneum, pericardium & pleura) is lined by *simple squamous epithelium*Q and distal convulated tubule (DCT) is lined by *simple cuboidal epithelium without brush border*Q

85. The toughest layer of the esophagus is the

a) Mucosa

b) Submucosa

c) Muscularis

d) Adventitia

Correct Answer - C

C i.e. Muscularis

- The **esophagus** contains four **layers**—the mucosa, submucosa, muscularis, and tunica adventitia.
- The mucosa is made up of stratified squamous epithelium containing numerous mucous glands.
- The submucosa is a thick, loose fibrous **layer** connecting the mucosa to the muscularis.
- The muscularis is composed of an inner layer, in which the fibres are circular, and an outer layer of longitudinal fibres.
- Both muscle groups are wound around and along the alimentary tract, but the inner one has a very tight spiral, so that the windings are virtually circular, whereas the outer one has a very slowly unwinding spiral that is virtually longitudinal.
- Muscularis is the *toughest layer of esophagus*; upper 1/3rd is composed of *skeletal muscle*, lower 1/3rd is composed of smooth muscle & the middle third is made up of both types of muscle.
- The tunica adventitia, is composed of loose fibrous tissue that connects the esophagus with neighbouring structures

86. Dorello's canal transmits in tip of temporal bone:

a) Middle meningeal artery

b) Mandibular nerve

c) Superior alveolar branch of maxillary

d) Abducent nerve

Correct Answer - D

D. i.e. Abducent nerve

Dorello canal is an opening to cavernous sinus that transmit *abducent nerve* underneath the *superior petrosal sinus*

87. While doing thoracocentesis, it is advisable to introduce needle along:

a) Upper border of the rib.

b) Lower border of the rib

c) Lower border of the rib

d) In anterior part of intercostal space.

Correct Answer - A
A i.e. Upper border of rib:

88. Bochdalek hernia occurs in

a) Anterolateral part of diaphragm

b) Posterolateral part of diaphragm

c) Retrosternal area

d) Posterior to diaphragm

Correct Answer - B
B i.e. Posterolateral part of diaphragm

89. IInd constriction in oesophagus is seen at the following site :

a) Where it crosses left main bronchus

b) Crossing of aorta

c) At pharyngoesophageal junction

d) Where it pierces the diaphragm

Correct Answer - B
B i.e. Crossing of Aorta

90. True regarding bronchopulmonary segment is /are

a) Avascular intersegmental planes

b) Complete vascular segment

c) Pulmonary vein occupy central position

d) One segment drains in >1 pulmonary vein

Correct Answer - D

D i.e. 1 Segment drains in > 1 pulmonary vein

91. Procerus muscle is continuation of which muscle?

a) Occipito-frontalis

b) Masseter

c) Medial pterygoid

d) Temporalis

Correct Answer - A

Ans. is'a'i.e., Occipitofrontalis

Procerus is often partially blended with, the medial side of frontal part of occipitofrontalis

92. Which of the following statements is true about the autonomic nervous system?

- a) The sympathetic outflow from the CNS is through both the cranial nerves and the sympathetic chain
- b) The parasympathetic outflow from the CNS is through cranial nerves only.
- c) The superior hypogastric plexus is located at the anterior aspect of the aortic bifurcation and fifth lumbar vertebra
- d) The superior hypogastric plexus contains sympathetic fibres only.

Correct Answer - C

C i.e. The superior hypogastric plexus is located at the anterior aspect of aortic bifurcation and fifth lumbar vertebra.

93. Ape thumb deformity is seen in involvement of :

a) Median nerve

b) Ulnar nerve

c) Radial nerve

d) Axillary nerve

Correct Answer - A
A i.e. Median Nerve

94. Tympanic plexus is formed by-

a) Tympanic branch of glosopharyngeal nerve

b) Vagus nerve

c) Gacial nerve

d) Mandibular nerve

Correct Answer - A

A i.e. Tympanic branch of glosopharyngeal nerve

95. Taste sensation to anterior 2/3 of tongue is supplied by

a) Glossopharyngeal nerve

b) Jacobson's nerve

c) Trigeminal nerve

d) Chorda tympani nerve

Correct Answer - D
D. i.e. Chorda tympani nerve

96.

Lower part of vagina develops from:

a) Urogenital sinus

b) Mesonephric duct

c) Paramesonephric duct

d) Mesonephric tubules

Correct Answer - A

Development of vagina

- Upper 2/3' : It is derived from *Utero-Vaginal Canal*, i.e. the fused part of paramesonephric duct. Therefore, this part is mesodermal in origin.
- Lower 1/3' : It is derived from *sinovaginal bulb* which inturn is derived from *urogenital sinus*. Thus, this part is *endodermal* in origin.

97. Arch of aorta develops from:

a) Right fourth aortic arch artery

b) Left third aortic arch artery

c) Left fourth aortic arch artery

d) Right third aortic arch artery

Correct Answer - C

Ans. Ans. C: Left fourth aortic arch artery

The fourth aortic arch persists on both sides, but its ultimate fate is different on the right and left sides.

- On the left it forms part of the arch of the aorta, between the left common carotid and the left subclavian arteries.
- On the right it forms the most proximal segment of the right subclavian artery, the distal part of which is formed by a portion of the right dorsal aorta and the seventh intersegmental artery

98. Trigone of urinary bladder develops from:

a) Mesoderm

b) Ectoderm

c) Endoderm of urachus

d) None of the above

Correct Answer - A

- With differential growth of the dorsal bladder wall, the ureters come to open through the lateral angles of the bladder, and the mesonephric ducts open close together in what will be the urethra.
- That part of the dorsal bladder wall marked off by the openings of these four ducts forms the trigone of the bladder.
- Thus, lining of the bladder over the trigone is mesodermal in origin;
- The smooth muscle of the bladder wall is derived from the splanchnopleuric mesoderm.
- The apex of the bladder is continuous with the allantois, which now becomes obliterated and forms a fibrous core, the urachus.
- The urachus persists throughout life as a ligament that runs from the apex of the bladder to the umbilicus and is called the median umbilical ligament

**99. All form the posterior wall of axilla
EXCEPT:**

a) Subscapularis

b) Subclavius

c) Teres major

d) Latissimus dorsi

Correct Answer - B
Subclavius forms the anterior wall of axilla

100. Musculocutaneous nerve supplies all of the following EXCEPT:

a) Coracobrachialis

b) Biceps brachii

c) Brachialis

d) Brachioradialis

Correct Answer - A

Suprascapular nerve arises from the upper trunk (formed by the union of the fifth and sixth cervical nerves).

101. Nerve roots involved in Erb's palsy:

a) C5, C6

b) C6, C7

c) C7, C8, T1

d) C5, C6, C7, C8, T1

Correct Answer - A

Erb-Duchenne Palsy

Upper lesions of the brachial plexus are injuries resulting from excessive displacement of the head to the opposite side and depression of the shoulder on the same side. This causes excessive traction or even tearing of C5 and C6 roots of the plexus. It occurs in infants during a difficult delivery or in adults after a blow to or fall on the shoulder.

The suprascapular nerve, the nerve to the subclavius, and the musculocutaneous and axillary nerves all possess nerve fibers derived from C5 and C6 roots and will therefore be functionless. The following muscles will consequently be paralyzed: the supraspinatus (abductor of the shoulder) and infraspinatus (lateral rotator of the shoulder); the subclavius (depresses the clavicle); the biceps brachii (supinator of the forearm, flexor of the elbow, weak flexor of the shoulder) and the greater part of the brachialis (flexor of the elbow) and the coracobrachialis (flexes the shoulder); and the deltoid (abductor of the shoulder) and the teres minor (lateral rotator of the shoulder).

Thus, the limb will hang limply by the side, medially rotated by the unopposed sternocostal part of the pectoralis major; the forearm will be pronated because of loss of the action of the biceps.

The position of the upper limb in this condition has been likened to that of a porter or waiter holding for a tip. In addition, there will be a

that of a porter or waiter tipping for a tip. In addition, there will be a loss of sensation down the lateral side of the arm.

Treatment

The three most common treatments from Erb's Palsy are: Nerve transfers (usually from the opposite leg), sub scapularis releases and latissimus dorsi tendon transfers.

102. Structures piercing clavipectoral fascia are all except:

a) Cephalic vein

b) Thoracoacromial artery

c) Lateral pectoral nerve

d) Basilic vein

Correct Answer - D

The clavipectoral fascia is a strong sheet of connective tissue that is attached above to the clavicle.

Below, it splits to enclose the pectoralis minor muscle and then continues downward as the suspensory ligament of the axilla and joins the fascial floor of the armpit.

The coracoclavicular fascia is pierced by the cephalic vein, thoracoacromial artery and vein, lymphatics passing from the breast and pectoral region to the apical group of axillary lymph nodes and lateral pectoral nerve.

103. The order of neurovascular bundle in the intercostal space from above downwards is:-

a) VAN

b) ANV

c) AVN

d) VNA

Correct Answer - A

The spaces between the ribs contain three muscles of respiration: the external intercostal, the internal intercostal, and the transversus thoracis muscle.

The intercostal nerves and blood vessels run between the intermediate and deepest layers of muscles. They are arranged in the following order from above downward: intercostal vein, intercostal artery, and intercostal nerve (i.e., VAN).

104. Bifurcation of trachea is at which level:

a) Opposite the disc between the T3-T4 vertebrae

b) Opposite the disc between the T5-T6 vertebrae

c) Opposite the disc between the T4-T5 vertebrae

d) Opposite the disc between the T7-T8 vertebrae

Correct Answer - C

The trachea begins in the neck as a continuation of the larynx at the lower border of the cricoid cartilage at the level of the sixth cervical vertebra.

- In the cadaver, trachea ends below at the carina by dividing into right and left principal (main) bronchi at the level of the sternal angle (opposite the disc between the fourth and fifth thoracic vertebrae).
- In living subjects, in the erect posture, the bifurcation lies at the lower border of the sixth thoracic vertebra.
- In adults the trachea is about 10-15 cm long and 2 cm in diameter.
- The fibroelastic tube is kept patent by the presence of U-shaped bars (rings) of hyaline cartilage embedded in its wall.
- The posterior free ends of the cartilage are connected by smooth muscle, the trachealis muscle.

105. Branches of left coronary artery are all of the following except:

a) Anterior interventricular branch

b) Left diagonal artery

c) Left atrial artery

d) Posterior interventricular branch

Correct Answer - D

The left coronary artery, which is usually larger than the right coronary artery, supplies the major part of the heart, including the greater part of the left atrium, left ventricle, and ventricular septum.

- It arises from the left posterior aortic sinus of the ascending aorta.
 - It then enters the atrioventricular groove and divides into an anterior interventricular branch and a circumflex branch. Branches
 - The anterior interventricular (descending) branch /left anterior descending (LAD) runs downward in the anterior interventricular groove to the apex of the heart.
 - The anterior interventricular branch supplies the right and left ventricles with numerous branches that also supply the anterior part of the ventricular septum. One of these ventricular branches (left diagonal artery) may arise directly from the trunk of the left coronary artery.
 - The left circumflex artery (LCX) is the same size as the anterior interventricular artery. It winds around the left margin of the heart in the atrioventricular groove. A left marginal artery is a large branch that supplies the left margin of the left ventricle down to the apex. Anterior ventricular and posterior ventricular branches supply the left ventricle. Atrial branches supply the left atrium.
- Posterior interventricular branch: It is typically a branch of the right

coronary artery (80%, known as right dominance). Alternately, the Posterior interventricular branch can be a branch of the left circumflex coronary artery (20%, known as left dominance) which itself is a branch of the left coronary artery

106. True about arch of aorta are all of the following except:

- a) Situated behind the lower half of the manubrium sterni
- b) Right common carotid artery arises from the arch of aorta
- c) It ends at the sternal end of the left second costal cartilage
- d) Beginning and end of the arch lies at same level

Correct Answer - B

The arch of the aorta is a continuation of the ascending aorta.

- It lies behind the manubrium sterni and arches upward, backward, and to the left in front of the trachea (its main direction is backward).
- It then passes downward to the left of the trachea and, at the level of the sternal angle, becomes continuous with the descending aorta.

Branches

- The brachiocephalic artery arises from the convex surface of the aortic arch.
 - It passes upward and to the right of the trachea and divides into the right subclavian and right common carotid arteries behind the right sternoclavicular joint.
- The left common carotid artery arises from the convex surface of the aortic arch on the left side of the brachiocephalic artery. It runs upward and to the left of the trachea and enters the neck behind the left sternoclavicular joint.
- The left subclavian artery arises from the aortic arch behind the left common carotid artery.
 - It runs upward along the left side of the trachea and the esophagus to enter the root of the neck.
 - It arches over the apex of the left lung.

107. Structures passing through diaphragm through aortic hiatus are all except:

a) Aorta

b) Azygous vein

c) Thoracic duct

d) Hemiazygous vein

Correct Answer - D

Aortic opening lies at the level of T12 vertebrae. It transmits:

- Aorta
- Thoracic duct
- Azygous vein

108.

True about Thoracic part of sympathetic trunk:

- a) The first five ganglia give preganglionic fibers
- b) The sympathetic trunk has 13 segmentally arranged ganglia
- c) It is the most medially placed structure in the mediastinum
- d) The first ganglion is often fused with the inferior cervical ganglion to form the stellate ganglion

Correct Answer - D

Thoracic Part of the Sympathetic Trunk is continuous above with the cervical and below with the lumbar parts of the sympathetic trunk. It is the most laterally placed structure in the mediastinum and runs downward on the heads of the ribs.

It leaves the thorax on the side of the body of the 12th thoracic vertebra by passing behind the medial arcuate ligament. The sympathetic trunk has 12 (often only 11) segmentally arranged ganglia, each with white and gray rami communicantes passing to the corresponding spinal nerve.

The first ganglion is often fused with the inferior cervical ganglion to form the stellate ganglion.

Branches

- The postganglionic fibers are distributed through the branches of the spinal nerves to the blood vessels, sweat glands, and erector pili muscles of the skin.
- The first five ganglia give postganglionic fibers to the heart, aorta, lungs, and esophagus.
- The lower eight ganglia mainly give preganglionic fibers, which are grouped together to form the splanchnic nerves and supply the abdominal viscera.



109. Base of the heart is formed mainly by:

a) Right atrium

b) Left atrium

c) Right ventricle

d) Left ventricle

Correct Answer - B

The heart has three surfaces: sternocostal (anterior), diaphragmatic (inferior), and a base (posterior).

It also has an apex, which is directed downward, forward, and to the left.

The sternocostal surface is formed mainly by the right atrium and the right ventricle.

The right border is formed by the right atrium; the left border, by the left ventricle and part of the left auricle.

The diaphragmatic surface of the heart is formed mainly by the right and left ventricles. The inferior surface of the right atrium, into which the inferior vena cava opens, also forms part of this surface.

The base of the heart, or the posterior surface, is formed mainly by the left atrium, into which open the four pulmonary veins.

110. Arch of aorta begins and ends at which level:

a) T2

b) T3

c) T4

d) T5

Correct Answer - C

The arch of the aorta (Transverse Aorta) begins at the level of the upper border of the second sternocostal articulation of the right side, and runs at first upward, backward, and to the left in front of the trachea; it is then directed backward on the left side of the trachea and finally passes downward on the left side of the body of the fourth thoracic vertebra, at the lower border of which it becomes continuous with the descending aorta.

111. Azygos vein drains into:

a) Left brachiocephalic vein

b) Inferior vena cava

c) Superior vena cava

d) Right brachiocephalic vein

Correct Answer - C

The azygos vein ends by joining the posterior aspect of the superior vena cava

The Azygos Vein

- The azygos vein connects the superior **and inferior venae** cavae, either directly by joining the IVC or indirectly by the hemiazygos and accessory hemiazygos veins.
- The azygos vein drains blood from the posterior walls of the thorax and abdomen.
- It ascends in the posterior mediastinum, passing close to the **right Q^A des** of the bodies of the inferior eight thoracic vertebrae (T4-T12).
- It is covered anteriorly by the oesophagus as it passes posterior to the root of the right lung.
- It then arches over the superior aspect of this root to join the SVC.
- In addition to the posterior intercostal veins, the azygos vein communicates with the vertebral venous plexuses.
- This vein also receives the mediastinal, oesophageal, and bronchial veins.

112. Talus bone articulates with all of the following EXCEPT:

a) Calcaneum

b) Tibia

c) Navicular

d) Cuboid

Correct Answer - D

Proximal surface of cuboid articulates with calcaneum, distal surface with 4th and 5th metatarsal and medial surface articulates with lateral cuneiform bone.

113. All of the following statements regarding the deep fascia of the thigh are true except:

a) It splits in the gluteal region to enclose gluteus maximus muscle

b) Iliotibial tract forms a sheath for tensor fasciae latae muscle

c) Medially the fascia is thickened to form iliotibial tract

d) It is also known as fascia lata

Correct Answer - C

Deep Fascia of the Thigh's (Fascia Lata) upper end is attached to the pelvis and the inguinal ligament. On its lateral aspect, it is thickened to form the iliotibial tract, which is attached above to the iliac tubercle and below to the lateral condyle of the tibia. The iliotibial tract receives the insertion of the tensor fasciae latae and the greater part of the gluteus maximus muscle.

In the gluteal region, the deep fascia forms sheaths, which enclose the tensor fasciae latae and the gluteus maximus muscles.

The saphenous opening is a gap in the deep fascia in the front of the thigh just below the inguinal ligament. It transmits the great saphenous vein, some small branches of the femoral artery, and lymph vessels.

The saphenous opening is filled with loose connective tissue called the cribriform fascia.

114. Left ovarian vein drains into:

a) Common iliac vein

b) Left renal vein

c) Inferior vena cava

d) Internal iliac vein

Correct Answer - B

Ovarian vein/ Female gonadal vein

- It carries deoxygenated blood from its corresponding ovary to inferior vena cava or one of its tributaries
- It is the female equivalent of the testicular vein, and is the venous counterpart of the ovarian artery.
- It can be found in the suspensory ligament of the ovary
- It is a paired vein, each one supplying an ovary.
 - The right ovarian vein travels through the suspensory ligament of the ovary and generally joins the inferior vena cava.
 - The left ovarian vein, unlike the right, often joins the left renal vein instead of the inferior vena cava.

115. Ovarian artery is a branch of:

a) Renal artery

b) Internal iliac artery

c) Abdominal part of the aorta

d) External iliac artery

Correct Answer - C

- The ovarian artery arises from the abdominal part of the aorta at the level of the first lumbar vertebra. The artery is long and slender and passes downward and laterally behind the peritoneum. It crosses the external iliac artery at the pelvic inlet and enters the suspensory ligament of the ovary.
- It then passes into the broad ligament and enters the ovary by way of the mesovarium.

116. Lymphatic drainage of ovary is through:

a) Preaortic and para-aortic lymph nodes

b) Superficial inguinal lymph nodes

c) Deep inguinal lymph nodes

d) Internal iliac lymph nodes

Correct Answer - A

Lymph Drainage of ovary

The lymph vessels of the ovary follow the ovarian artery and drain into the pre aortic and para-aortic nodes at the level of the first lumbar vertebra.

Arterial Supply

The ovarian artery arises from the abdominal aorta at the level of the first lumbar vertebra.

Venous drainage.

The ovarian vein drains into the inferior vena cava on the right side and into the left renal vein on the left side. Nerve Supply

The nerve supply to the ovary is derived from the aortic plexus and accompanies the ovarian artery.

117. All of the following veins lack valves except

a) Femoral vein

b) Portal vein

c) IVC

d) Dural venous sinuses

Correct Answer - A

Veins which do not have valves are:

- IVC
- SVC
- Hepatic, ovarian, uterine, renal, emissary, cerebral, pulmonary, and umbilical veins
- Portal venous system is a valveless system

Note: Inferior vena cava :- Orifice is guarded by a rudimentary valve of IVC (Eustachian valve) derived from embryonic right venous valve, which directs the blood from IVC towards foramen ovale in fetal life. This valve is nonfunctional in adults.

118. Superior thyroid artery originates from:

a) Internal carotid artery

b) External carotid artery

c) Facial artery

d) Maxillary artery

Correct Answer - B

Branches of the External Carotid Artery Superior thyroid artery

Ascending pharyngeal artery

Lingual artery

Facial artery

Occipital artery

Posterior auricular artery

Superficial temporal artery

Maxillary artery

119. Number of parathyroid glands in human:
September 2005

a) 4

b) 3

c) 2

d) 5

Correct Answer - A

- The parathyroid glands are ovoid bodies measuring about 6 mm long in their greatest diameter.
- They are four in number and are closely related to the posterior border of the thyroid gland, lying within its fascial capsule.
- The two superior parathyroid glands are the more constant in position and lie at the level of the middle of the posterior border of the thyroid gland.
- The two inferior parathyroid glands usually lie close to the inferior poles of the thyroid gland. They may lie within the fascial sheath, embedded in the thyroid substance, or outside the fascial sheath

120. Internal jugular vein is the continuation of which of the following sinus

a) Cavernous sinus

b) Sigmoid sinus

c) Inferior petrosal sinus

d) Superior petrosal sinus

Correct Answer - B

Internal jugular vein is the direct continuation of the sigmoid sinus

The sigmoid sinuses:

- They are two areas beneath the brain which allow blood to drain inferiorly from the posterior center of the head.
- They drain from the transverse sinuses and converge with the inferior petrosal sinuses to form the internal jugular vein
- Each sigmoid sinus begins beneath the temporal bone and follows a tortuous course to the jugular foramen, at which point the sinus becomes continuous with the internal jugular vein

The internal jugular vein:

- It collects the blood from the brain, from the superficial parts of the face, and from the neck.
- It is directly continuous with the transverse sinus, and begins in the posterior compartment of the jugular foramen, at the base of the skull.
- The thoracic duct on the left side and the right lymphatic duct on the right side open into the angle of union of the internal jugular and subclavian veins.

The external jugular vein:

- It is formed by the junction of the posterior division of the posterior

facial with the posterior auricular vein.

- It commences in the substance of the parotid gland, on a level with the angle of the mandible.

The anterior jugular vein:

- It begins near the hyoid bone by the confluence of several superficial veins from the submaxillary region.
- It descends between the median line and the anterior border of the Sternocleidomastoideus, and, at the lower part of the neck, passes beneath that muscle to open into the termination of the external jugular, or, in some instances, into the subclavian vein

121.

Which of the following is not the part of ethmoid bone?

a) Agger nasi

b) Crista galli

c) Uncinate process

d) Inferior turbinate

Correct Answer - D

Ans. d. Inferior turbinate

Inferior turbinate is not the part of ethmoid bone.

`Lateral nasal wall has 3 bony projections called as turbinates or conchae. From below upwards, they are inferior, middle and superior turbinates. The inferior turbinate is a separate bone, while rest of the turbinates are part of ethmoidal labyrinths.'

The agger nasi air cells, are the most anterior ethmoidal air cells, lying anterolateral and inferior to the frontoethmoidal recess and anterior and above the attachment of the middle turbinate. They are located within the lacrimal bone and therefore have as lateral relations the orbit, the lacrimal sac and the nasolacrimal duct.'

The crista galli is a median ridge of bone that projects from the cribriform plate of the ethmoid bone. It is where the falx cerebri attaches anteriorly to the skull. The olfactory bulbs lie on either side of the crista galli on top of the cribriform plate.'

In the ethmoid bone, a curved lamina, the uncinat process, projects downward and backward from this part of the labyrinth; it forms a small part of the medial wall of the maxillary sinus, and articulates with the ethmoidal process of the inferior nasal concha.'

122. 1st carpometacarpal joint is?

a) Pivot

b) Hinge

c) Ball and Socket

d) Saddle

Correct Answer - D
Saddle

123. Femoral nerve supplies all except ?

a) Pectineus

b) Sartorius

c) Vastus medialis

d) Obturator externus

Correct Answer - D

Branches of femoral nerve are :?

1. *From the main trunk* :- Nerve supply to iliacus, nerve supply to pectineus and a few vascular branches.
2. *From anterior division* :- Intermediate femoral cutaneous nerve (intermediate cutaneous nerve of thigh), medial femoral cutaneous nerve (medial cutaneous nerve of thigh) and muscular branch to sartorius.
3. *From posterior division* :- Saphenous nerve, nerve supply to quadriceps femoris (rectus femoris, vastus medialis, vastus lateralis, vastus intermedius).
4. *Articular supply* :- Hip joint is supplied by nerve to rectus femoris; knee joint is supplied by nerve to three vasti.

124. Portocaval anastomosis is seen at all of the following places, except?

a) Gastroesophageal junction (lower end of esophagus)

b) Rectum

c) Spleen

d) Liver

Correct Answer - C
Spleen

125. Axillary artery is divided into three parts by?

a) 1st rib

b) Clavicle

c) Pectoralis minor muscle

d) Teres minor muscle

Correct Answer - C

Axillary artery

- It is the main artery of upper limb. *It begins at the level of outer border of first rib as a continuation of subclavian artery.* It ends at the level of lower border of teres major to continue as brachial artery.
- The axillary artery is covered anteriorly by pectoralis minor, which divides it into three parts:?
 - 1) First part :- This part is proximal to upper border of pectoralis minor, i.e. extends from outer border of first rib to upper border of pectoralis minor. The branch of first part is *Superior thoracic artery*.
 - 2) Second part :- This part is behind pectoralis minor. It gives following branches.
 - A) *Thoracoacromial artery* :- It pierces clavipectoral fascia and gives following branches :-
 - (i) *Acromial*
 - (ii) *Pectoral*,
 - (iii) *Clavicular and deltoid*.
 - B) *Lateral thoracic artery*
 - 3) Third part :- This part is distal to lower border of pectoralis minor, i.e. extends from pectoralis minor (lower border) to teres major (lower border). It gives following branches ?
 - A) *Subscapular artery*:- It gives off *circumflex scapular artery* and

then continues as *thoracodorsal artery*.

B) *Anterior circumflex humeral artery*.

C) *Posterior circumflex humeral artery*.

- Anterior and posterior circumflex arteries (both are branches of 3rd part of axillary artery) forms anastomosis around surgical neck of humerus.

126. Submandibular gland is divided into superficial and deep parts by ?

a) Digastric

b) Geniohyoid

c) Mylohyoid

d) Stylohyoid

Correct Answer - C

Submandibular gland

- This walnut sized gland lies below the mandible in the anterior part of digastric triangle. It is *.1-shaped* and consists of a large superficial and a small deep parts, separated by mylohyoid muscle and continuous with each other around the posterior border of mylohyoid muscle.

Superficial part

- It is situated in the anterior part of digastric triangle. The gland is partially closed in a capsule formed by two layers of deep cervical fascia. It has three surfaces : (i) inferior, (ii) lateral, and (iii) medial.
 - i) Inferior surface* is covered by skin, platysma, cervical branch of facial nerve, deep fascia, facial vein and submandibular lymph nodes.
 - ii) Lateral surface* is related to submandibular fossa (on mandible), medial pterygoid (insertion) and facial artery.
 - iii) Medial surface* is related to mylohyoid, hyoglossus and styloglossus muscles.

Deep part

- It lies on the hyoglossus muscle deep to mylohyoid. It is related above to lingual nerve and submandibular ganglion; and below to hypoglossal nerve.



127. Nerve entering the inguinal canal through deep inguinal ring ?

a) Ilioinguinal nerve

b) Pudendal nerve

c) Genital branch of genitofemoral

d) Superior rectal nerve

Correct Answer - C

The spermatic cord in males and round ligament of uterus in females, enter the inguinal canal through the deep inguinal ring and pass out through superficial inguinal ring.

Thus constituents of spermatic cord are also components of inguinal canal; these are ductus deferens (vas deferens), testicular artery, cremasteric artery, artery to ductus deference, pampiniform plexus, lymphatics, sympathetic plexus, *genital branch of genitofemoral nerve*, remains of process vaginalis.

Note: Ili oiguinal nerve enters inguinal canal through interval between external and internal oblique muscles (not through deep inguinal ring).

128.

Not a part of bony labyrinth?

a) Cochlea

b) Vestibule

c) Utricle

d) Semicircular canal

Correct Answer - C

The inner ear within the *petrous part of temporal bone* consists of a membranous labyrinth enclosed in a bony (osseous) labyrinth. So, inner ear has two parts : ?

1) *Bony labyrinth* :- Cochlea, Vestibule, Semicircular canals.

2) *Membranous labyrinth* :- Cochlear duct, utricle, Saccules, three semicircular ducts, and endolymphatic duct & sac.

129. Organ of corti is situated in ?

a) Basilar membrane

b) Utricle

c) Sacculle

d) None of the above

Correct Answer - A

Scala media (cochlear duct or membranous labyrinth) has 3 walls : -

- i) The basilar membrane, which supports the organ of corti.
- ii) The Reissner's membrane which separates it from the scala vestibuli.
- iii) The stria vascularis which contains vascular epithelium and is concerned with secretion of endolymph.

130. Nerve which loops around submandibular duct?

a) Mandibular nerve

b) Lingual nerve

c) Hypoglossal nerve

d) Recurrent laryngeal nerve

Correct Answer - B

Submandibular duct

- It is 5 cm long duct and runs forwards on hyoglossus, between lingual and hypoglossal nerves.
- At the anterior border of the hyoglossus muscle it is crossed by lingual nerve which loops around it.
- *It opens into the floor of mouth, on the summit of the sublingual papilla at the side of frenulum of tongue.*

131. Posterior to transverse pericardial sinus?

a) Aorta

b) Pulmonary trunk

c) SVC

d) Left atrium

Correct Answer - C

Ans. is 'c' i.e., SVC

- Transverse sinus is a short passage that lies between the reflection of serous pericardium (epicardium) around arterial (aorta and pulmonary trunk) and venous ends of the heart tube.
- Transverse sinus is bounded anteriorly by ascending aorta and pulmonary trunk, *posteriorly by SVC, and inferiorly by left atrium.*

132. Wiscott Aldrich syndrome commonly consists of following except?

a) Recurrent bacterial infections

b) Eczema

c) Bleeding

d) Urethritis

Correct Answer - D
Urethritis

133. Internal thoracic artery is a branch of ?

a) Common carotid artery

b) Brachiocephalic trunk

c) Subclavian artery

d) External carotid artery

Correct Answer - C

Internal thoracic artery

It arises from 1st part of subclavian artery and descends through anterior ends of upper six intercostal spaces lying 1.25 cm lateral to sternal margin.

It divides into two terminal branches, *musculophrenic and superior epigastric* in 6th intercostal space.

Branches of internal thoracic artery are (i) mediastinal branches, (ii) pericardial branches, (iii) sternal branches, (iv) pericardiophrenic branches, (v) anterior intercostal arteries (in upper six spaces), (vi) perforating branches, and (vii) two terminal branches, musculophrenic and superior epigastric.

134. Which is not a branch of anterior division of internal iliac artery ?

a) Inferior vesical

b) Internal pudendal

c) Iliolumbar

d) Inferior gluteal

Correct Answer - C

Branches of anterior division of internal iliac artery are :

- (i) Superior vesical
- (ii) Middle rectal
- (iii) Inferior *vesical* (in males),
- (iv) Internal *pudendal*,
- (v) Vaginal (in females),
- (vi) *Uterine* (in females)
- (vii) *Obturator*
- (viii) Inferior *gluteal*.

Branches of posterior division are : (i) Iliolumbar, (ii) Lateral sacral, and (iii) Superior gluteal.

135. 'Gut tube is developed from which germ layer

a) Ectoderm

b) Mesoderm

c) Endoderm

d) Neuroectoderm

Correct Answer - C

The gut is derived from the yolk sac, and hence is endodermal in origin.

136. Adduction at wrist is caused by ?

a) Flexor carpi radialis

b) Extensor pollicis longus

c) Extensor carpi ulnaris

d) Flexor digitorum profundus

Correct Answer - C

Ans. C. Extensor carpi ulnaris

Origin and insertion:

- It originates from the lateral epicondyle of the humerus and the posterior border of the ulna, and crosses the forearm to the ulnar (medial) side to insert at the base of the 5th metacarpal.

Action:

- The extensor carpi ulnaris extends the wrist, but when acting alone inclines the hand toward the ulnar side; by its continued action it extends the elbow-joint.
- The muscle is a minor extensor of the carpus in carnivores, but has become a flexor in ungulates. In this case it is described as ulnaris lateralis.

Innervation:

- Despite its name, the extensor carpi ulnaris is innervated by the posterior interosseous nerve (C7 and C8), the continuation of the deep branch of the radial nerve.
- It would therefore be paralyzed in an injury to the posterior cord of the brachial plexus.

137. Which of the following does not directly drain into right atrium ?

a) Great cardiac vein

b) Anterior cardiac vein

c) Thebasian vein

d) Venae cordis minimi

Correct Answer - A

Great cardiac vein

Great cardiac vein does not directly drain into right atrium. It drains into coronary sinus, which in turn drains into right atrium.

Veinous drainage of heart

1. *Coronary sinus* : Opens into *right atrium* and has following tributaries :
(i) Great cardiac vein, (ii) Middle cardiac vein, (iii) Posterior vein of left ventricle, (iv) Small cardiac vein, (v) Oblique vein of left atrium and (vi) Sometimes right marginal vein.
2. *Anterior cardiac vein* : Opens into *right atrium*.
3. *Venae cordis minimi (thebasian veins)* : All these are extremely small veins in the walls of all the 4 chambers of the heart. They open directly into the respective chambers. They're most numerous in the right atrium.
4. *Right marginal vein* : More often opens into right atrium but sometimes into coronary sinus.

138. Which structures passes along with esophagus through esophageal opening of diaphragm ?

a) NC

b) Gastric nerves

c) Aorta

d) Thoracic duct

Correct Answer - B
Gastric nerves

139. Which of the following is false regarding coronary circulation ?

a) Anterior 2/3 of septum is supplied by LCA

b) Posterior 1/3 of septum is supplied by RCA

c) Right bundle branch is supplied by RCA

d) Left bundle branch is supplied by LCA

Correct Answer - C

Right coronary artery supplies (i) SA node (in 65%), (ii) whole conducting system (AV bundle, bundle of his, part of left bundle branch) except RBB and part of left branch of AV bundle, (iii) posterior part of ventricular septum, (iv) most of right ventricle except small part adjoining anterior interventricular groove and small part of left ventricle adjoining posterior interventricular groove.

Left coronary artery supplies (i) most of the left atrium, (ii) most of the left ventricle including apex, (iii) small part of right ventricle adjoining anterior interventricular septum, (iv) anterior 2/3 of ventricular septum, (v) RBB, LBB and (vi) SA node in 35% of cases.

140. True about umbilical cord ?

- a) Contains two umbilical veins
- b) Contains one umbilical artery
- c) Right umbilical vein disappears
- d) Length is 25-30 cm.

Correct Answer - C

Umbilical cord

Umbilical cord develops from connecting stalk, which extends from the caudal end of the embryo to the chorion.

Umbilical cord is covered by *amniotic epithelium* and contains a core of mesenchyme known as *whartan's jelly*.

Contents of umbilical cord are : (i) *Wharton's jelly*, (ii) Two umbilical arteries, (iii) One (left) umbilical vein, (iv) Remnant of yolk sac, and (v) Remnant of allanto-enteric diverticulum.

Initially 2 umbilical arteries and 2 umbilical veins develop in mesoderm, but right umbilical vein disappears. Left umbilical vein persists along with 2 umbilical arteries.

At full term, the umbilical cord measures 1-2cm in diameter, and 50-55cm in length and generally attached to the center of fetal surface of placenta.

**141. All are attached to coracoid process,
except?**

a) Coracobrachialis

b) Pectoralis minor

c) Short head of biceps

d) Long head of biceps

Correct Answer - D
Long head of biceps

142. Respiratory bronchiole proceed into ?

a) Terminal bronchiole

b) Bronchi

c) Tertiary bronchiole

d) Alveolar duct

Correct Answer - D

Respiratory tract anatomy

- Nasal cavity, oral cavity, pharynx and larynx forms upper respiratory tract. Larynx opens into lower respiratory tract which starts from Trachea. Trachea bifurcates into bronchi (principal bronchi). Progressive branching of bronchi forms *bronchioles*. Further branching of bronchioles leads to *terminal bronchioles*. Terminal bronchiole emnate into *respiratory bronchioles*. *Respiratory bronchioles* proceed into the *alveolar ducts*, wich immediately branch into *alveolar sacs (alveoli)*.

143. Mandibular nerve passes through ?

a) Foramen rotundum

b) Foramen lacerum

c) Stylomastoid foramen

d) Foramen ovale

Correct Answer - D
Foramen ovale

144. Prostatic artery is a branch of ?

a) Superior vesical artery

b) Middle vesical artery

c) Inferior vesical artery

d) Superior rectal artery

Correct Answer - C

Prostate is supplied by branches (prostatic branches) of :-

- i) *Inferior vesical artery*
- ii) *Middle rectal artery*
- iii) *Internal pudendal artery*

145. True about pectinate line ?

- a) Blood supply above pectinate line is through superior rectal artery
- b) Lymphatic drainage above pectinate line is through superficial inguinal nodes
- c) Part above pectinate line develops from proctodeum
- d) Part above pectinate line is supplied by somatic nerves

Correct Answer - A

Blood supply above pectinate line is through superior rectal artery
Part of anal canal above pectinate line develops from dorsal part of *endodermal cloaca* (primitive rectum) and part of anal canal below pectinate line develops from *ectodermal proctodeum*.

Mucous membrane above pectinate line is supplied by autonomic nerves (sympathetic L₁ L₂ and parasympathetic: S₂ S₃ S₄) and therefore is insensitive to pain. Part below the pectinate line is supplied by somatic nerves (inferior rectal nerve a branch of pudendal nerve) and therefore is sensitive to pain. Thus pain sensations are carried by pudendal nerve.

Pectinate line forms the *water-shed line* of anal canal. Area above pectinate line drains into internal iliac nodes and area below it drains into superficial inguinal nodes.

Arterial supply of the area is above pectinate line is through superior rectal artery (continuation of inferior mesenteric artery) and area below pectinate line is supplied by inferior rectal artery.

146. All muscles of pharynx are supplied by pharyngeal plexus except -

a) Palatopharyngngeus

b) Stylopharyngeus

c) Salpingopharyngeus

d) Superior constrictor

Correct Answer - B

All muscles of pharynx are supplied by cranial accessory through branches of vagus via pharyngeal plexus except stylopharyngeus which is supplied by glossopharyngeal.

The inferior constrictor receives an additional supply from the external and recurrent laryngeal nerves.

147. Posterior belly of digastric is supplied by

a) Facial nerve

b) Mandibular nerve

c) Glossopharyngeal nerve

d) Trochlear nerve

Correct Answer - A
Ans. is 'a' i.e., Facial nerve

148. Appendix of testis is derived from ?

a) Cranial end of mesonephric duct

b) Caudal end of mesonephric duct

c) Caudal end of paramesonephric duct

d) Caudal end of paramesonephric duct

Correct Answer - C
, Cranial end of paramesonephric duct

149. Internal thoracic artery is a branch of ?

a) 1st part of subclavian artery

b) 2nd part of subclavian artery

c) 3rd part of subclavian artery

d) Thyrocervical trunk

Correct Answer - A
1st part of subclavian artery

150. Posterior interosseous artery is a branch of ?

a) Radial artery

b) Ulnar artery

c) Brachial artery

d) Axillary artery

Correct Answer - B

Ulnar artery

It is the *larger terminal branch of brachial artery*, arising in the cubital fossa. In the distal two-third of forearm, it is accompanied by ulnar nerve. It enters the palm by passing superficial to flexor retinaculum and divides into superficial and deep terminal branches, just distal to pisiform. Its branches are ?

A) In cubital fossa

1) *Anterior ulnar recurrent*

2) *Posterior ulnar recurrent*

3) *Common interosseous* :- Divides into

i) *Anterior interosseous*

ii) *Posterior interosseous*

1) Palmar carpal branch

2) Dorsal carpal branch

C) In palm :- These are terminal branches.

1) *Deep branch*

2) *Superficial branch*

151. Gland of Moll are modification of which gland

a) Sebaceous gland

b) Holocrine gland

c) Sweat glands

d) None

Correct Answer - C
Sweat glands

152. True regarding origin and insertion of piriformis ?

a) Origin from sacrum & ilium and insertion on LT

b) Origin from sacrum & ilium and insertion on GT

c) Origin from ischeal tuberosity and insertion on LT

d) Origin from ischeal tuberosity and insertion on GT

Correct Answer - B

Origin from sacrum & ilium and insertion on GT

153. Central nervous system develops from ?

a) Ectoderm

b) Endoderm

c) Mesoderm

d) All three germ layers

Correct Answer - A

Nervous system develops from ectoderm (neuroectoderm).

154. True about deep palmar arch ?

a) Main contribution is by ulnar artery

b) Lie superficial to lumbricals

c) Gives three perforating branches

d) Gives four palmar metacarpal arteries

Correct Answer - C

Deep palmar arch

- It lies across the base of metacarpal bones. It is formed mainly by radial artery and completed by deep branch of ulnar artery. Its branches are :-
 - i. *Three palmar metacarpal arteries* on the II, III and IV palmar interossei muscles to join the digital branches of superficial palmar arch.
 - i. *Three perforating arteries* :- Anastomose with dorsal metacarpal arteries.
 - i. *Recurrent branches* :- Supply carpal bones and join palmar carpal arch.
- The deep palmar arch lies deep to the oblique head of adductor pollicis, long flexor tendon and lumbrical muscles and passes across the base of metacarpal and interossei.

155. Branches of internal thoracic artery are all except

a) Superior epigastric

b) Musculophrenic

c) Anterior intercostal

d) Posterior intercostal

Correct Answer - D

Internal thoracic artery

- It arises from 1st part of subclavian artery and descends through anterior ends of upper six intercostal spaces lying 1.25 cm lateral to sternal margin.
- It divides into two terminal branches, *musculophrenic and superior epigastric* in 6th intercostal space.
- Branches of internal thoracic artery are (i) mediastinal branches, (ii) pericardial branches, (iii) sternal branches, (iv) pericardiophrenic branches, (v) anterior intercostal arteries (in upper six spaces), (vi) perforating branches, and (vii) two terminal branches, musculophrenic and superior epigastric.

156. Ligament teres is a remnant of ?

a) Ductus arteriosus

b) Umbilical artery

c) Umbilical vein

d) Ductus venosus

Correct Answer - C
Umbilical vein

157. Right border of heart is formed by ?

a) Right ventricle

b) Right atrium

c) SVC

d) IVC

Correct Answer - B

External features of heart

The heart has following borders and surfaces :-

A) Borders

i) *Right border* :- Formed by right atrium.

ii) *Left border (obtuse margin)*:- Formed mainly by left ventricle and partly by left auricle (in its upper most part).

iii) *Inferior border (acute margin)*:- Formed mainly by right ventricle and partly by left ventricle near apex.

iv) *Upper border* :- Mainly by left atrium and partly by right atrium where SVC enters.

v) *Apex* :- Formed by left ventricle.

B) Surfaces

i) *Anterior (sternocostal) surface* :- Formed mostly by right ventricle (major) and right auricle and partly by left ventricle and left auricle.

ii) *Inferior (diaphragmatic) surface* :- It is formed by left ventricle (left 2/3) and right ventricle (right 1/3). It is traversed by posterior interventricular groove (PIV) containing PIV branch of RCA.

158. Thoracic duct enters from abdomen to thorax at ?

a) T6

b) T10

c) T12

d) T8

Correct Answer - C

- Thoracic duct is also called as Pecquet duct. It is the *largest lymphatic duct* in body, about 45 cm (18 inches) long. o It has a *beaded appearance* because of the presence of many valves in its lumen.
- Thoracic duct begins as a continuation of the upper end of the cisterna chyli near the lower border of T₁₂ vertebra and enters the thorax through the aortic opening of diaphragm (at T₁₂).
- It then ascends through the posterior mediastinum and at T₅ level crosses from right side to the left side and ascends along left margin of oesophagus to enter the neck.
- At the level of C₇ vertebrae, arches towards left side to open into left brachiocephalic vein at the angle of union of left subclavian and left internal jugular veins.

159. Morrison's pouch is ?

a) Right subphrenic space

b) Right subhepatic space

c) Left subhepatic space

d) Left subphrenic space

Correct Answer - B

These spaces are just below diaphragm in relation to the liver.

These space are :

1) Intraperitoneal spaces are :-

- i. Left anterior space (left subphrenic space).
- i. Left posterior space (left subhepatic space or *lesser sac*).
- i. Right anterior space, (right subphrenic space).
- i. Right posterior space (right subhepatic space or *hepatorenal pouch* or *Morrison's pouch*).

2) Extraperitoneal spaces are :-

- i. Right and left extraperitoneal spaces.
- i. Midline extraperitoneal space (*Bare area of liver*).

160. Prussak's space is related to -

a) Mesotympanum

b) Epitympanum

c) Hypotympanum

d) Inner ear

Correct Answer - B

The middle ear lies between the tympanic membrane laterally and the cochlea medially. The middle ear (tympanic cavity) is divided into :?

A) Mesotympanum (tympanic cavity proper)

It is the *narrowest part of tympanic cavity (transverse dimension is 2 mm)*. It lies opposite to pars tensa.

B) Epitympanum (attic)

It is the part of tympanic cavity which extends above the tympanic membrane (pars tensa) and lies opposite (medial) to shrapnel's membrane (pars flacida) and bony lateral attic wall. It is the *widest part of tympanic cavity (transverse dimension is 6 mm)*.

Epitympanum (attic) communicates with mastoid air cell system, through a small opening called *aditus*. *Prussak's space* communicates with epitympanum through a posterior gap. Attic area (epitympanum) is a crowded place and only a thin plate of bone (tegmen) separates this region from middle cranial fossa. Any infection in this area is prone to affect the temporal lobe of brain through erosion of this plate. Infections and inflammations in this area are considered to be unsafe due to impending intracranial complications.

161.

Maximum number of mucosal folds are found in which part of fallopian tube

a) Infundibulum

b) Ampulla

c) Isthmus

d) Interstitial part

Correct Answer - B

Mucosa of fallopian tube

Mucosa of fallopian tube is folded to form numerous longitudinal folds which project into the lumen. *Maximum numbers of these folds are present in the ampulla.*

- The mucosa is covered by simple columnar epithelium.
- The epithelium has two types of cells :?
 - .. Ciliated cells
 - ?. Non-ciliated secretory cells (*peg cells*)
- Secretion of peg cells provides nutrition to ovum.

162. Derivative of dorsal mesogastrium ?

a) Lesser omentum

b) Greater omentum

c) Falciform ligament

d) Triangular ligament

Correct Answer - B
Greater omentum

163.

Septum transversum gives rise to which part of diaphragm ?

a) Right crus

b) Left crus

c) Central tendon

d) Peripheral costal portion

Correct Answer - C
Central tendon

164. Not an abductor of shoulder ?

a) Deltoid

b) Trapezius

c) Supraspinatus

d) Latissimus dorsi

Correct Answer - D

Latissimus dorsi

- Abduction is initiated by supraspinatus, which is responsible abduction upto 15° . After that deltoid (acromial or middle fibers) is the major abductor upto 90° of abduction. These two muscles, supraspinatus and deltoid are the prime movers for abduction.
- Overhead abduction ($> 90^\circ$) is caused by trapezius and serratus anterior, which act by causing upward rotation of glenoid cavity.

165. De-Quervain's tenosynovitis affects ?

a) FPL & FPB

b) EPL & APL

c) EPB & APL

d) FDP & FDS

Correct Answer - C

- De-Quervian's tenovaginitis is characterized by pain over *the styloid process of the radius* and palpable thickening in the course of the *abductor pollicis longus and extensor pollicis brevis tendons*.
- The *fibrous sheaths* of the abductor pollicis longus and extensor pollicis brevis tendons are thickened where they cross the tip of the radial styloid process.
- The tendons themselves appear normal as does the synovial lining of sheath.

166. Which leaves the pelvis ?

a) Piriformis

b) Sciatic nerve

c) Superior gluteal vessel

d) Inferior gluteal vessel

Correct Answer - B

- Sciatic nerve leaves the pelvis and runs posteriorly in the thigh.
- In the upper angle of popliteal fossa, sciatic nerve divides into tibial nerve and common peroneal nerve

167. Supination in flexed elbow is produced by ?

a) Supinator

b) Biceps

c) Coracobrachialis

d) Brachialis

Correct Answer - B
Ans. B. Biceps

168. Lymph from glans penis drains into ?

a) Superficial inguinal nodes

b) Deep inguinal lymph nodes

c) Obturator nodes

d) Internal iliac nodes

Correct Answer - B

Vessels from the glans penis drain into the deep inguinal lymph nodes (gland of Cloquet)

From rest of the penis, lymph drains into the superficial inguinal lymph nodes.

169. True about subarachnoid space ?

a) Between dura and arachnoid

b) Outside subdural space

c) Between dura and bone

d) Surround the conus

Correct Answer - D

- Subarachnoid space is the space between arachnoid and pia maters
- It is inside (deep) to subdural space.
- Spinal cord ends at L₁ level as conus medullaris and subarachnoid space ends at S2 level. Thus subarachnoid space surrounds the conus medullaris completely.

170. Colon is supplied by all except ?

a) Inferior mesenteric artery

b) Ileocolic artery

c) Middle colic artery

d) Internal iliac artery

Correct Answer - D

The blood supply of colon is derived from the marginal artery of Drummond. It is a paracolic anastomotic artery formed by anastomosis between *colic branches of superior mesenteric artery (ileocolic, right colic, middle colic) and colic branches of inferior mesenteric artery (left colic and sigmoidal arteries)*. Terminal branches from marginal artery are distributed as long and short vessels *vasa longa* and *vasa bravia*.

- There are areas of colon with poor blood supply resulting from incomplete anastomosis of marginal arteries. These are watershed areas of colon and include :
 1. Splenic flexure (Griffith point) : Watershed area between superior mesenteric artery and inferior mesenteric artery.
 2. Rectosigmoid junction (Sudeck's point) : Watershed zone between *inferior mesenteric artery and internal iliac artery*.

171. Crista terminalis is present in ?

a) Left atrium

b) Left ventricle

c) Right atrium

d) Right ventricle

Correct Answer - C

Crista terminalis (divides the right atrium into anterior and posterior part) is a ridge of smooth muscle fibers extending from the SVC to valve of IVC.

It is developed from *embryonic right venous valve* and is represented on the surface by *sulcus terminalis*.

172. Ligament of Lockwood is seen at ?

a) Ear

b) Palate

c) TM joint

d) Orbit

Correct Answer - D

Fascia! sheath of eye ball (Bulbar fascia)

Tenon's Capsule is a fascial sheath around eye ball.

This fascial sheath is *pierced by* tendons of extraocular muscles and ciliary nerves and vessels. o Tenon's capsule (fascial sheath) gives following expansions :?

1. *Tubular sheath* which covers each orbital muscle.
2. *Medial check ligament* is a triangular expansion from sheath of medial rectus; it is attached to lacrimal bone.
3. *Lateral check ligament* is a triangular expansion from sheath of *lateral rectus* and is attached to zygomatic bone.

173. All are true about bronchopulmonary segment except -

- a) Have independent single artery
- b) Have independent single vein
- c) Pyramidal in shape
- d) Have a independent segmental tertiary bronchus

Correct Answer - B

Each bronchopulmonary segment is drained by intersegment parts of pulmonary vein that lie in intersegmental space and drain adjacent segments.

Thus each segment does not have its independent segmental vein and each segment drains into more than one vein. Each vein drains more than one segment.

Features of bronchopulmonary segments

Characteristic features of each bronchopulmonary segment are :?

- 1) Is a pyramidal shaped segment of lung, with its apex facing the lung root and its base at the pleural surface.
- 2) Is the largest subdivision of a lobe.
- 3) Is an independent respiratory unit.
- 4) Is separated from adjacent segments by connective tissue septa which form intersegmental planes.
- 5) Is surrounded by connective tissue which is continuous on the surface with pulmonary pleura.
- 6) Is supplied independently by a segmental (tertiary) bronchus and a tertiary branch of the pulmonary artery.
- 7) Is named according to the segmental bronchus supplying it.
- 8) Is drained by intersegmental parts of the pulmonary veins that lie in intersegmental space and drain adjacent segments. Thus each

segment has more than one vein and each vein drains more than one segment.

9) Is not a bronchovascular segment, because it does not have its own vein.

10) Is surgically resectable : During removal, the surgeon works along the pulmonary vein to isolate a particular segment.

174. Nerve that winds around neck of fibula ?

a) Tibial nerve

b) Deep peroneal nerve

c) Superficial peroneal nerve

d) Common peroneal nerve

Correct Answer - D

Common peroneal nerve *winds around neck of fibula to enter peroneus longus muscle*. Because of its subcutaneous position it can be easily palpated here and is very prone to injury. So fracture neck of fibula may cause *foot drop*.

175. Structure developing from Mullerian duct in males?

a) Seminal vesicle

b) Epididymis

c) Prostatic utricle

d) Ureter

Correct Answer - C

Remnants of *Mullerian duct (paramesonephric duct)* in males are:-

i) Appendix of testis (Hydatid of Morgagni)

ii) Prostatic utricle.

176. Reichert's cartilage derivative is ?

a) Malleus

b) Incus

c) Stapes suprastructure

d) Sphenomandibular ligament

Correct Answer - C

The cartilage of second pharyngeal arch (hyoid arch) is known as *Reichert's cartilage* and contributes as :- (i) Stapes (except footplate), (ii) Styloid process, (iii) Stylohyoid ligament, (iv) Lesser cornu and superior part of body of hyoid bone.

However, footplate of stapes develop from otic capsule.

177. Middle turbinate is a ?

a) Separate bone

b) Part of ethmoid

c) Part of sphenoid

d) Part of zygomatic

Correct Answer - B

There are three turbinates in the lateral wall of nose : superior, middle and inferior.

The inferior turbinate is a separate bone, while rest of the turbinates are a part of ethmoidal bone.

Below and lateral to each turbinate is the corresponding meatus.

Inferior turbinate is longest one.

178. Root of mesentery is crossed by ?

a) Left testicular artery

b) Left ovarian artery

c) IVC

d) Left ureter

Correct Answer - C

Attached border of mesentery (root of mesentery) crosses -

1. *Third (horizontal) part of duodenum*
2. *Abdominal aorta*
3. **IVC**
4. *Right ureter*
5. *Right psoas major*

179. All are true about boundaries of epiploic foramen except -

a) Anterior : portal vein & hepatic artery

b) Posterior : IVC

c) Inferior : liver

d) Inferior : duodenum

Correct Answer - C

Epiploic foramen (foramen of Winslow or aditus to lesser sac) is a slit-like opening through which lesser sac communicates with greater sac. It is situated at the level of T₁₂ vertebra. Its boundaries are :-

- Anterior :- Right free margin of lesser omentum (contains portal vein, hepatic artery proper and bile duct).
- Posterior :- IVC, right suprarenal gland and T₁₂ vertebra.
- Superior :- Caudate lobe of liver.
- Inferior :- 1st part of duodenum and horizontal part of hepatic artery.

180. Climbing fibres of cerebellar cortex are ?

a) Olivocerebellar fibres

b) Spinocerebellar fibres

c) Pontocerebellar fibres

d) Vestibulocerebellar fibres

Correct Answer - A

Input (afferent) cerebellum comes from two fibres.

1) *Climbing fibres (olivocerebellar fibres)* bring information from *inferior olivary nuclei only*.

2) *Mossy fibres* bring information from all other parts of the body.

181. Deep branch of ulnar nerve supplies all except ?

a) Adductor pollicis

b) Abductor digiti minimi

c) Flexor digiti minimi

d) Opponens pollicis

Correct Answer - D

Various branches of ulnar nerve are :?

A) In arm : No branch.

B) In forearm : There are following branches :?

1) *Muscular* : In proximal part of forearm it supplies flexor carpi ulnaris and **medial** half of flexor digitorum profundus.

2) *Cutaneous* : There are two cutaneous branches in forearm:-

i) *Palmar cutaneous branch* : Supplies skin over the hypothenar eminence.

ii) *Dorsal (posterior) cutaneous branch* : Supplies skin over medial 1/3 of dorsum of hand and dorsal surface of medial 1 1/2 fingers.

C) In hand : Ulnar nerve enters the palm by passing superficial to flexor retinaculum and divides into two terminal branches :?

1) *Superficial terminal branch* : It supplies *palmaris brevis* and skin of palmar surface of medial 1 1/2 fingers.

2) *Deep terminal branch* : It supplies adductor pollicis, all interossei, medial two (3rd & 4th) lumbricals and all hypothenar muscles except palmaris brevis (i.e. abductor digiti minimi, flexor digiti minimi, opponens digiti minimi).

182. Internal arcuate fibers of medulla comes from ?

a) Dorsal nucleus of vagus

b) Hypoglossal nucleus

c) Nucleus of tractus solitariu

d) Nucleus gracilis & cuneatus

Correct Answer - D

Ans. is 'd' i.e., Nucleus gracilis & cuneatus

The nucleus gracilis and cuneatus give rise to the *internal arcuate fibres*.

The fibres cross to the opposite side where they form a paramedian band of fibres, called the *medial lemniscus*.

In the lemniscus, the body is represented with the head posteriorly and the feet anteriorly.

183. True about terminal bronchioles are all except ?

a) Absence of cartilage

b) Presence of clara cells

c) Absence of smooth muscles

d) Absence of submucous glands

Correct Answer - C

- Terminal bronchioles contain Clara cells which secrete a protein that lines the small air passages. Alveoli (alveolar sac) are lined by type 1 pneumocytes (95%) and type 2 pneumocytes (5%). Type 2 pneumocytes secrete surfactant and also helps in repair of alveoli after destruction of type- 1 pneumocytes. Pores of Kohn are present in alveolar wall to allow passage of bacteria and exudate between adjacent alveoli.
- Terminal bronchi contain maximum smooth muscle cells relative to wall thickness.
- Cartilage is found in larynx, trachea and bronchi but not in bronchioles.
- Submucosal glands are particularly numerous in medium-sized bronchi and disappear in distal terminal bronchioles.

184. Anterior horn of lateral ventricle is closed anteriorly by -

a) Thalamus

b) Septum pellucidum

c) Lamina terminalis

d) Corpus callosum

Correct Answer - D

Anterior horn of lateral ventricle is closed anteriorly by the genu and rostrum of corpus callosum.

Lateral ventricle

Two lateral ventricles are the *cavities of cerebral hemisphere (one in each hemisphere)*. Each lateral ventricle communicates with third ventricle through *interventricular foramen of Monro*.

It is divisile into four parts :?

1) Central part (body) : It is located in the medial parts of frontal and parietal lobes. It extends from interventricular foramen (of Monro) in front to splenium of corpus callosum behind. It *has choroid plexus*. It has :-

- o *Roof* : Formed by corpus callosum.

i. *Floor* : Formed form lateral to medial by caudate nucleus (body), stria terminalis, thalamostriate vein, and lateral part of upper surface of thalamus.

i. *Medial wall (partition between two lateral ventricles)* : By septum pellucidum and body of fornix.

2) Anterior horn : It lies in front of interventricular foramen of Monro extending into the frontal lobe. It *has no choroid plexus*. Its bondries are :-

- *Anterior* : Posterior surface of genu and rostrum of corpus callosum.
- *Roof* : Anterior part of trunk of corpus callosum.

- *Floor* : Head of caudate nucleus and upper surface of rostrum of corpus callosum.
 - *Medial (partition)* : Septum pellucidum and column of fornix.
- 3) Posterior horn : It lies behind splenium of corpus callosum and extends into occipital lobe. It may be variable in size (*may be absent*). It *has no choroid plexus*. Its boundaries are :-
- i. *Floor and medial wall* : Bulb of posterior horn raised by forceps major and calcar avis, an elevation raised by calcarine sulcus (anterior part).
 - i. *Roof and lateral wall* : Tapetum
- 4) Inferior horn : It is *the largest horn* and extends into *temporal lobe*. It *has choroid plexus*. Its boundaries are
- i. *Roof and lateral wall* : Tapetum, tail of caudate nucleus, stria terminalis and amygdaloid body.
 - i. *Floor* : *Collateral eminence* (elevation by collateral sulcus) and hippocampus medially.

185.

Axillary nerve is a branch of which part of brachial plexus ?

a) Trunk

b) Medial cord

c) Lateral cord

d) Posterior cord

Correct Answer - D

Supraclavicular branches of brachial plexus

Branches of brachial plexus which are above the clavicle are called supraclavicular branches.

These *arise from roots and trunks.*

186. True about relations of renal artery and vein ?

- a) Left renal vein passes behind aorta
- b) Renal artery passes in front of IVC
- c) Right renal vein shorter than left renal vein
- d) Renal artery is a branch of internal iliac artery

Correct Answer - C

Ans. is 'c' i.e., Right renal vein shorter than left renal vein

Renal vasculature

Each kidney is supplied by renal artery (branch of abdominal aorta) and is drained by *renal vein to IVC*. o Renal artery :- Right renal artery is longer and passes behind IVC. Renal artery divides into : ?

a) *Posterior division* :- Supplies posterior segment.

b) *Anterior division* :- Divides further into 4 branches to supply apical, upper anterior, middle anterior and lower segments.

Renal vein :- Left renal vein is longer and passes in front of abdominal aorta, behind the origin of superior mesenteric artery.

Therefore, it may be compressed in the narrow angle between the two arteries. Left renal vein also receives left inferior phrenic vein, left gonadal vein and left suprarenal (adrenal) vein. Each renal vein begins beneath the true capsule as stellate vein.

187. The length of esophagus in adult is ?

a) 10cm

b) 15cm

c) 20 cm

d) 25 cm

Correct Answer - D

Esophagus

It is a narrow muscular tube measuring 25 cm long connecting pharynx with stomach.

It begins as a continuation of laryngopharynx at the level of lower border of cricoid cartilage at the level of C6 vertebrae and passes through the diaphragm at the level of T₁₀ through esophageal hiatus of diaphragm.

It ends at T₁₁ level by opening into cardiac orifice of stomach.

Oesophagus does not have straight course rather it presents anteroposterior curvatures.

It is lined by stratified squamous nonkeratinized epithelium.

Esophagus is divided into three parts (i) Cervical part (4 cm), (ii) Thoracic part (20 cm), and (iii) abdominal part (1-2 cm).

188. Not a middle mediastinal structure ?

a) Pulmonary trunk

b) Phrenic nerve

c) Thymus

d) Heart

Correct Answer - C
Thymus

189. Tributary of coronary sinus ?

a) Anterior cardiac vein

b) Thebesian vein

c) Smallest cardiac vein

d) Great cardiac vein

Correct Answer - D

Coronary sinus

It opens *in* the posterior wall of right atrium, in the posterior part of *coronary sulcus*.

It opens in the right atrium between IVC and tricuspid orifices.

Tributaries of coronary sinus are :

i) *Great cardiac vein* :- Lies in the anterior interventricular groove.

Left marginal vein drains into it.

ii) *Middle cardiac vein* :- Lies in the posterior interventricular groove.

iii) *Posterior vein of left ventricle*.

iv) *Small cardiac vein* :- It lies in the *posterior part of coronary sulcus with RCA*. *Right marginal vein may sometimes open into small cardiac vein, more often, however, right marginal vein opens directly into right atrium.*

v) *Oblique vein of left atrium (vein of Marshall)* :- It is continuous above with ligament of IVC. These two structures are embryological remnants of left common cardinal vein (duct of Cuvier).

190. Ulnar nerve supplies all except ?

a) FCU

b) 1st lumbrical

c) 4th lumbrical

d) Dorsal interossei

Correct Answer - B
1st lumbrical

191. Temporal lobe contains ?

a) Primary visual area

b) Primary auditory area

c) Broca's area

d) Prefrontal area

Correct Answer - B

Functional areas of cerebral cortex

1. **Frontal lobe**

2. **Parietal lobe**

3. **Occipital lobe**

4. **Temporal lobe contains :-**

- *i) Primary auditory area (areas 41, 42):* Located in the anterior part of transverse temporal gyri of Heschl, and posterior part of superior temporal gyms.
- *ii) Auditory association cortex (secondary auditory area or area 22) :* It also includes Wernick's speech and is located in the posterior part of superior temporal gyrus

Occipital lobe

192.

Mastoid antrum is present in which part of temporal bone?

a) Tympanic

b) Petrous

c) Squamous

d) Mastoid

Correct Answer - B

Mastoid

- It is an air sinus in the petrous temporal bone.
- Its upper anterior wall has the opening of aditus, while medial wall is related to posterior semicircular canal (SCC).
- Posteriorly lies the sigmoid sinus.
- The posterior belly of digastric muscle forms a groove in the base of mastoid bone.
- The corresponding ridge inside the mastoid lies lateral not only to sigmoid sinus but also to facial nerve and is a useful landmark.
- The roof is formed by tegmen antri separating it from middle cranial fossa and temporal lobe of brain. o Anteroinferior is the descending part of facial nerve canal (*or fallopian canal*).
- Lateral wall is formed by squamous temporal bone and is easily palpable behind the pinna.

193. Not a content of deep perineal pouch ?

a) Membranous urethra

b) Artery of the penis

c) Urethral artery

d) Bulbourethral glands

Correct Answer - C
Urethral artery

194. True about attachments at ischeal tuberosity ?

- a) Origin of semitendinosus from superolateral area
- b) Origin of semimembranosus from superolateral area
- c) Origin of long head of biceps from superolateral area
- d) Origin of adductor magnus from superolateral area

Correct Answer - B

Attachments of ischeal tuberosity -

- i) Superolateral* Origin of *semimembranosus*.
 - ii) Inferomedial* :- Origin of *semitendinosus* and *long head of biceps*.
 - iii) Outer lower area* :- Origin of *adductor magnus* .
- Medial margin gives attachment to *sacrospinous ligament*.
Lateral border gives attachment to *ischiofemoral ligament*.

195. Anterior division of femoral nerve supplies ?

a) Rectus femoris

b) Sartorius

c) Iliacus

d) Pectineus

Correct Answer - B

Branches of femoral nerve are :?

1) *From the main trunk* :- Nerve supply to iliacus, nerve supply to pectineus and a few vascular branches.

2) *From anterior division* :- Intermediate femoral cutaneous nerve (intermediate cutaneous nerve of thigh), medial femoral cutaneous nerve (medial cutaneous nerve of thigh) and muscular branch to sartorius.

3) *From posterior division* :- Saphenous nerve, nerve supply to quadriceps femoris (rectus femoris, vastus medialis, vastus lateralis, vastus intermedius).

4) *Articular supply* :- Hip joint is supplied by nerve to rectus femoris; knee joint is supplied by nerve to three vasti.

196. All form the boundaries of ovarian fossa, except ?

a) Ureter

b) Internal pudendal artery

c) Obliterated umbilical artery

d) Internal iliac artery

Correct Answer - B

Each ovary lies in ovarian fossa on the lateral pelvic wall which is bounded :-

i) Anteriorly : Obliterated umbilical artery

ii) Posteriorly : Ureter and internal iliac artery

197. Wrist drop is due to injury to ?

a) Radial nerve

b) Ulnar nerve

c) Median nerve

d) Posterior interosseous nerve

Correct Answer - A

Clinical features of radial nerve palsy

- Clinical features depend upon the site of lesion.
 - 1) If lesion is high
 - Wrist drop, thumb drop and finger drop.
 - Inability to extend elbow, wrist, thumb & fingers (MP joint)
 - Patient can extend interphalangeal joints due to action of lumbricals and interossei.
 - Sensory loss over posterior surface of arm & forearm and lower lateral half of forearm.
 - 2) If lesion is low
 - a) *Type I*
 - Wrist drop, thumb drop and finger drop.
 - Elbow extension is preserved.
 - Sensory loss over the dorsum of first web space.
 - b) *Type II*
 - Thumb drop and finger drop
 - Elbow and wrist extension is preserved
 - Sensory loss over the dorsum of first web space.

198. Equinus deformity refers to ?

- a) Inversion of foot
- b) Eversion of foot
- c) Plantar flexion at ankle
- d) Dorsi flexion at ankle

Correct Answer - C

Equinus deformity refers to plantar flexion at ankle joint with inability to do dorsi-flexion.

It may be either congenital or acquired.

Most common cause is contracture of gostracnemius or soleus or both.

199. Carpal bone which articulates with radius ?

a) Trapezium

b) Scaphoid

c) Capitate

d) Hamate

Correct Answer - B

Two carpal bones articulate with radius: Scaphoid and lunate.

200. Nerve supply of opponens pollicis ?

a) Superficial branch of ulnar nerve

b) Deep branch of ulnar nerve

c) Median nerve

d) Posterior interosseous nerve

Correct Answer - C

Hand muscles supplied by median nerve are :-

i) *Thenar muscles (except adductor pollicis) :- Flexor pollicis brevis, opponens pollicis and abductor pollicis brevis. Adductor pollicis is supplied by ulnar nerve.*

ii) First two lumbricals.

Hand muscles supplied by ulnar nerve are :?

1) *Superficial terminal branch* : It supplies *palmaris brevis* and skin of palmar surface of medial 1st fingers.

2) *Deep terminal branch* : It supplies adductor pollicis, all interossei, medial two (3rd & 4th) lumbricals and all hypothenar muscles except palmaris brevis (i.e. abductor digiti minimi, flexor digiti minimi, opponens digiti minimi).

201. Nerve supply of pronator teres ?

a) Ulnar nerve

b) Median nerve

c) Posterior interosseous

d) Radial nerve

Correct Answer - B
Median nerve

202. Ribs are developed from ?

a) Cloaca

b) Sclerotome

c) Endodermal cloaca

d) Primitive gut

Correct Answer - B

Ribs are derived from lateral cells of sclerotome.

Derivatives of paraxial mesoderm

Paraaxial mesoderm is organized into somites which in turn gives rise to

i) *Sclerotomes* : Form axial skeleton including vertebrae, *ribs* and parts of neurocranium.

ii) *Myotomes* : Form all voluntary (skeletal) muscles of head, trunk and limbs.

iii) *Dermatomes* : Form dermis of skin, especially over dorsal regions.

203. Content of superficial perineal pouch ?

a) Sphincter urethrae

b) Deep transverse perinei

c) Bulbospongiosus

d) Artery of penis

Correct Answer - C
Bulbospongiosus

204. Ventricles of brain are lined by ?

a) Ependymocytes

b) Astrocytes

c) Oligodendrocytes

d) Podocytes

Correct Answer - A

Ventricles of brain are lined by ependyma (ependymocytes).

Ventricles of brain

These are *cavities in the brain* lined by ependyma and filled with CSF.

They contain choroid plexuses which secrete CSF.

These are four fluid filled intercommunicating cavities within the brain :-

i) Two lateral ventricles (right and left),

ii) Third ventricle, and

iii) Fourth ventricle. o Lateral ventricle communicates with third ventricle by *interventricular foramen (foramen of Monro)*.

Third ventricle communicates with fourth ventricle by cerebral aqueduct (*aqueduct of sylvius*).

Fourth ventricle communicates with subarachnoid space by a *median foramen (Magendie)* and two lateral (*Luschka*) foramina.

205. Liver segment which is physiologically independent?

a) Segment I

b) Segment II

c) Segment III

d) Segment IV

Correct Answer - A

Caudate lobe (segment I) is a physiological independent part of liver, supplied by both right and left hepatic arteries; right and left branches of portal vein and drains bile into both right and left hepatic duct.

206. Nerve supply of cremastic muscle ?

a) Pudendal nerve

b) Femoral branch of genitofemoral

c) Genital branch of genitofemoral nerve

d) Ilioinguinal nerve

Correct Answer - C

Genital branch of genitofemoral nerve

Cremastic muscle is a muscle of scrotum. It is supplied by genital branch of genitofemoral nerve.

207. Nerve supply above pectinate line is through ?

a) Inferior rectal nerve

b) Pudendal nerve

c) Autonomic nerves

d) Perineal branch of S₄

Correct Answer - C

Nerve supply of anal canal

Mucous membrane above pectinate line is supplied by autonomic nerves (sympathetic L₁ L₂ and parasympathetic: S₂ S₃ S₄) and therefore is insensitive to pain.

Part below the pectinate line is supplied by somatic nerves (inferior rectal nerve a branch of pudendal nerve) and therefore is sensitive to pain.

Thus pain sensations are carried by pudendal nerve.

208. Which of the following is not present in Deep perineal pouch ?

a) Bartholin's gland

b) Bulbourethral glands

c) Dorsal nerve of penis

d) Sphincter urethrae

Correct Answer - A

Great vestibular gland (Bartholin's gland) is a component of superficial perineal pouch.

209. Superficial perineal muscles include?

a) Iliococcygeus

b) Ischiococcygeus

c) Bulbospongiosus

d) Levator ani

Correct Answer - C

Superficial muscles of perineum (lie in superficial perineal pouch) are ischiocavernosus, bulbospongiosus and superficial transverse perinei.

Deep muscles (lie in deep perineal pouch) are sphincter urethrae, deep transverse perinei, and in females, compression urethrae and sphincter urethrovaginalis.

210. Cartilage in trachea ?

a) Hyaline

b) Elastic

c) Articular

d) Fibro

Correct Answer - A
Ans. is 'a' i.e., Hyaline

211. How many vascular segments are present in each kidney?

a) 3

b) 4

c) 5

d) 6

Correct Answer - C

Renal artery :- Right renal artery is longer and passes behind **IVC**.

Renal artery divides into : ?

a) *Posterior division* :- Supplies posterior segment.

b) *Anterior division* :- Divides further into 4 branches to supply apical, upper anterior, middle anterior and lower segments.

Thus, there are five vascular segments in each kidney :-

Posterior, apical, upper anterior, middle anterior and lower.

Branches of renal artery are end arteries.

212. Not under flexor retinaculum

a) Median nerve

b) Ulnar nerve

c) FDS

d) FPL

Correct Answer - B

Structures deep to flexor retinaculum

1) Lateral compartment : Flexor carpi radialis tendon with its synovial sheath lodged in the groove on the palmar surface of trapezium.

2 Medial compartment : (carpal tunnel proper).

Structures superficially to flexor retinaculum

1) Palmaris longus tendon continuous with apex of palmar aponeurosis.

2) Palmar cutaneous branch of median nerve.

3) Palmar cutaneous branch of ulnar nerve.

4) Ulnar nerve.

5) Ulnar vessels protected superficially by volar carpal ligament (superficial part of the flexor retinaculum).

213. Clavipectoral fascia splits to enclose subclavius and pectoralis minor, and continues as ?

a) Axillary sheath

b) Costocoracoid ligament

c) Costoclavicular ligament

d) Suspensory ligament

Correct Answer - D

Clavipectoral fascia

- It is a *strong sheet of fascia*, situated deep to pectoralis major muscle and extends from the pectoralis minor to the clavicle. It splits in upper part to enclose subclavius and splits in lower part to enclose pectoralis minor. Below this it is continuous as suspensory ligament.
- Traced upward, it splits to enclose the subclavius, and its two layers are attached to clavicle, one in front and the other behind. The latter layer fuses with *deep cervical fascia and axillary sheath*.
- Medially, clavipectoral fascia blends with the fascia covering first two intercostal spaces and is attached to first rib medial to origin of subclavius.
- Laterally, it is very thick and dense, and is attached to coracoid process. The portion extending from first rib to coracoid process is called costocoracoid ligament.

214. Internal rectal venous plexus lies at ?

a) Outer anal verge

b) White line of Hilton

c) Proximal to pectinate line

d) Distal to pectinate line

Correct Answer - C

- Internal rectal venous plexus (Hemorrhoidal plexus) lies above the pectinate line.
- It lies in the submucosa of anal canal and drains mainly into superior rectal vein, but communicates freely with external rectal venous plexus.
- The internal plexus is in the form of a series of dilated pouches and veins present in the 3, 7 and 11 O'clock positions are large and constitute potential sites from primary internal piles (hemorrhoids).

215.

Cervical part of esophagus all are true except?

a) Arise at cricoid level

b) Site of portosystemic anastomosis

c) Foreign body obstruction common at this level

d) Striated muscle fibres positive

Correct Answer - B

- Portosystemic (Porto caval) anastomosis is seen in lower part (abdominal part) of esophagus.
- Cervical esophagus begins at lower border of cricoid cartilage (at C6 vertebral level) as a downward continuation of pharynx.
- Muscularis externa of cervical esophagus contains only skeletal muscle (striated muscle) fibers.
- Foreign body obstruction is common in this part of esophagus.

216. True about SA node are all except ?

a) Supplied by nodal artery

b) Primary pacemaker

c) Supplied by left vagus nerve

d) Made up of nodal cells and connective tissue

Correct Answer - C

- SA node is located in the upper part of crista terminalis at the junction of SVC and the right atrium.
- It is the pacemaker of the heart and generates impulse at a rate of 70-100/min.
- SA node is supplied by nodal artery, a branch of RCA in 65% cases and a branch of circumflex branch of LCA in 35% cases.
- SA node is supplied by right vagus/parasympathetic (inhibitory) and right Sympathetic (excitatory) system as it develops from structures on the right side of embryo.
- *The SA node consists of connective tissue stroma containing an irregular whorled network of cardiac nodal cells, the SA nodal artery and numerous nerve endings (postganglionic parasympathetic and postganglionic sympathetic).*

217. Uterine artery is branch of ?

a) Anterior branch of internal iliac

b) Posterior branch of internal iliac

c) Anterior division of external iliac

d) Psterior division of external iliac

Correct Answer - A
Anterior branch of internal iliac

218. Portal vein is formed ?

a) Behind the spleen

b) Behind the tail of pancreas

c) Behind the neck of pancreas

d) Behind the second part of duodenum

Correct Answer - C

The portal vein is about 8 cm long.

It is formed by union of superior mesenteric vein and splenic vein behind the neck of pancreas at the level of **L₂** vertebrae in front of inferior vena cava (IVC).

219. At hilum of lung, what enters ?

a) Primary/Principal bronchus

b) Secondary bronchus

c) Tertiary bronchus

d) Bronchiole

Correct Answer - A

The root (hilum) of lung is made up of following structures :?

1. Principal bronchus on the left side, and eparterial and hyarterial bronchi on the right side.
2. One pulmonary artery.
3. Two pulmonary veins, superior and inferior.
4. Bronchial arteries, one on the right side and two on the left side.
5. Bronchial veins.
6. Anterior and posterior pulmonary plexuses of nerves.
7. Lymphatics of the lung.
8. Bronchopulmonary lymph nodes.
9. Areolar tissue.

220. Submental lymph nodes drains from ?

a) Centre of lower lips

b) Posterior 1/3 of tongue

c) Anterior 2/3 of tongue

d) Angle of mouth

Correct Answer - A

Submental lymph nodes

These lymph nodes lie on the mylohyoid in the *submental triangle*. They receive afferents from superficial tissue below chin, central part of lower lip, adjoining gums, anterior part of the floor of the mouth and tip of the tongue. These nodes, themselves, drain into (efferent) into submandibular nodes.

221. Supination - pronation occurs at ?

a) Wrist joint

b) Radiocarpal joint

c) Radio-ulnar joint

d) Elbow joint

Correct Answer - C
Radio-ulnar joint

222. Foreign body from trachea most common goes to right bronchus due to ?

a) Right bronchus shallow

b) Wider & in continuous line with trachea

c) Right bronchus is longer

d) Right bronchus is horizontal

Correct Answer - B

Trachea bifurcates at Carina (at lower border of T4 vertebra at T₄-T₅ disc space) into *right and left principal (primary) bronchi*.

Right principal bronchus is wider, shorter (2.5 cm long), and more vertical in the line of trachea (25° with median plane).

Therefore a foreign body is most likely to lodge in the right bronchus.

223. Inferior angle of scapula lies at -

a) T6

b) T7

c) T3

d) T12

Correct Answer - B

Important landmarks of scapula

- i) Inferior angle overlaps seventh rib or seventh intercostal space and lies opposite to tip of T7 spinous process.
- ii) Superior angle lies opposite to *tip of T2 spinous process*.
- iii) Lateral angle corresponds to glenoid fossa.
- iv) Junction of medial (vertebral) border corresponds to tip of T3 spine.

224.

Which of the following is situated in the upper part of Crista terminalis ?

a) AV node

b) Bundle of his

c) Right Bundle branch

d) SA node

Correct Answer - D
SA node

225. Cardiac ganglion is situated ?

a) Below arch of aorta

b) Above arch of aorta

c) Left side of ligamentum arteriosum

d) Posterior to ligamentum arteriosum

Correct Answer - A

Nerve supply of heart

- Nerve supply to the heart has both (i) *Motor*, and (ii) *Sensory components*.

Motor component

- i) Superficial cardiac plexus :-* Lies in front of right pulmonary artery below the arch of aorta. It is formed by:-
 - o *Superior cervical cardiac branch of the left sympathetic chain.*
- *Inferior cervical cardiac branch of left vagus.*
- A small ganglion, the cardiac ganglion of Wrisberg, is occasionally found connected with these nerves at their point of junction. This ganglion, when present, is situated immediately beneath the arch of aorta, on right side of ligamentum arteriosum.
- ii) Deep cardiac plexus :-* Lies in front of the bifurcation of trachea, behind the arch of aorta. *It is formed by all sympathetic and parasympathetic cardiac branches except those forming the superficial plexus.*

Sensory component

- Pain sensation arising due to ischemia is conveyed by afferents which pass through sympathetic cardiac fibers and reach the T₁ to T₄ cord segments on left side. Since these dorsal root ganglia also receive sensory impulses from the medial side of arm, forearm and upper part of front of chest, the pain gets referred to these areas

through these thoracic splanchnic nerves (T₁-T₄). Though the pain is usually referred to the left side, it may even be referred to right arm, jaw, epigastrium, neck, shoulder or back.

226. Which is not a boundary of calot triangle

a) Common hepatic duct

b) Cystic duct

c) Right lobe of liver

d) Gall bladder

Correct Answer - D
Gall bladder

227. During development spleen lobulation is related to ?

a) Lateral

b) Superior

c) Inferior

d) None

Correct Answer - B

Spleen develops as a collection of mesenchymal cells in the dorsal mesogastrium.

Initially the splenic tissue is arranged as a number of lobules which later join together to form a single spleen. The notches in the superior border of adult spleen are representatives of growth that separated the lobules during fetal period.

228. Appendix of testes is remnant of ?

a) Mesonephric duct

b) Paramesonephric duct

c) paramesonephric tubule

d) Mesonephric tubule

Correct Answer - B

Male's derivatives of paramesonephric duct (Mullerian duct) are :-

i) *Appendix of testis (Hydatid of morgagn)*.

ii) Prostatic utricle.

229. True about serratus anterior ?

a) Causes protraction

b) Causes lateral rotation

c) Supplied by thoracodorsal nerve

d) Forms lateral boundary of axilla

Correct Answer - A

Serratus anterior causes protraction of scapula.

- It is supplied by long thoracic nerve (Nerve of Bell).
- It forms medial boundary of axilla.

Serratus anterior

- *Origin* : Outer surface of upper 8 ribs by 8 digitations (multipennate muscles).
- *Insertion* : Medial border of scapula and inferior angle.
- *Nerve supply* : Long thoracic nerve (nerve of bell).
- *Actions* : Action of serratus anterior are -
- Rotates the scapula so that glenoid cavity is raised upward & forward - Helps in *Vertical over head abduction* (in this action assisted by trapezius).
- Draws the scapula forward around the thoracic wall so *paralysis leads to winging of scapula.*
- Also used when arm is pushed forward in horizontal position as in *forward punch* (helped by Pectoralis minor in this action).
- Steadies the scapula during weight carrying.
- Helps in *forced inspiration*.² (Accessory muscle of inspiration).
- Because of greater pull exerted on the inferior angle, inferior angle passes laterally and forward and the glenoid cavity is raised upward & forward; in this action the muscle is assisted by trapezius.

230. Which of the following is not a branch of external carotid artery ?

a) Supraorbital

b) Posterior auricular

c) Superficial temporal

d) Occipital

Correct Answer - A
Supraorbital

231. Stomach is derived from ?

a) Foregut

b) Midgut

c) Hindgut

d) Allantois

Correct Answer - A
Foregut

232. Fundus of uterus drains into ?

a) External iliac

b) Inguinal

c) Paraaortic

d) Obturator

Correct Answer - C

Paraaortic

- *Cervix (lower lymphatics) :-* Lymphatics drain into external iliac, internal iliac, and sacral nodes.
- *Lower part of body (middle lymphatics) :-* Lymphatics drain into the external iliac nodes.
- *Fundus and upper part of body (upper lymphatics) :-* Lymphatics drain mainly into para-aortic nodes and a few lymphatics from the uterine cornu accompany the round ligaments to reach the superficial inguinal nodes.

233. Fascia of Denonvilliers lies between

- a) Vagina and rectum
- b) Vagina and urinary bladder
- c) Prostate and rectum
- d) None of the above

Correct Answer - C

In males, rectovesicle pouch of peritoneum intervenes between rectum and urinary bladder.

Obliterated part of rectovesical pouch is called fascia of Denonviller's which separates posterior surface of prostate from rectum. In females rectouterine pouch (pouch of Douglas) lies between rectum (posteriorly) and uterus and posterior fornix of vagina (anteiorly). In females vesicouterine pouch lies between urinary bladder (anteriorly) and uterus posteriorly.

The rectovesical pouch (in males) and rectouterine pouch (in females) are the most dependent portions of peritoneal cavity in erect posture.

234. Urogenital diaphragm is pierced by all except -

a) Internal pudendal artery

b) Dorsal artery of penis

c) Dorsal nerve of penis

d) Urethra

Correct Answer - A

Male:

- Urethra, 2-3 cm behind the inferior border of the symphysis pubis.
- Vessels and nerves to the bulb of the penis.
- Ductus of the bulbourethral glands, posterolateral to the urethral orifice.
- Deep dorsal vessels and dorsal nerves of the penis, behind the pubic arch in the midline.
- Posterior scrotal vessels and nerves, anterior to the transverse perineal line.

Female:

- Urethra, 2-3 cm behind the inferior border of the symphysis pubis.
- Vagina, centrally
- Ducts of Bartholin's glands, posterolateral to the urethral orifice
- Deep dorsal vessels and dorsal nerves of the clitoris, behind the pubic arch in the midline.
- Posterior labial vessels and nerves, anterior to the transverse perineal line.

235. Which is not a lobe of lung ?

a) Azygous

b) Superior

c) Inferior

d) Lingual

Correct Answer - D

Fissure and lobes of lungs

The right lung is divided into 3 lobes (upper, middle and lower) by two fissures, oblique and horizontal. The left lung is divided into two lobes (upper and lower) by the oblique fissures. Each lobe is further subdivided into bronchopulmonary segments. Each lung has 10 bronchopulmonary segments.

236. Which is not true of mandible ?

- a) From second pharyngeal arch
- b) Body and ramus are its two parts
- c) Strongest bone of skull
- d) Has 16 sockets for teeth

Correct Answer - A

The *mandible*, or the lower jaw, is the largest and the strongest bone of the face.

It develops from the *first pharyngeal arch*. It has a horseshoe-shaped body which lodges the teeth, and a *pair of rami* which project upwards from the posterior ends of the *body*.

The rami provide attachment to the muscles of mastication.

Upper (alveolar) border of body bears sockets for teeth (usually 16).

237. Attachment at hook of hamate -

a) FCR

b) Flexor retinaculum

c) FCU

d) FDP

Correct Answer - B

The hamate :

- i) The tip of the hook gives attachment to the *flexor retinaculum*.
- ii) The medial side of the hook gives attachment to the *flexor digiti minimi* and the *opponens digiti minimi*.

238. Pericardial space is present between ?

- a) Endocardium and pericardium
- b) Epicardium and pericardium
- c) Endocardium and epicardium
- d) Parietal and visceral pericardium

Correct Answer - D

Pericardial space (pericardial cavity) lies between parietal serous pericardium and visceral serous pericardium.

239. Vasa Vasorum of ascending aorta arises from ?

a) Left coronary artery

b) Anterior interventricular artery

c) Posterior interventricular artery

d) Left atrium

Correct Answer - A

Clinical anatomy

"Both coronary arteries supply vasa vasorum of ascending aorta"

"Coronary arteries are vasa vasorum of ascending aorta"

Vasa vasorum of ascending aorta and arch of aorta arise from :

i) Coronary arteries (at their ostia).

ii) Brachiocephalic trunk.

iii) Bronchial artery.

Vasa vasorum of descending aorta arise from':

i) Intercostal arteries (thoracic part).

ii) Lumbar and mesenteric arteries (abdominal part).

240. True about nervi erigentes are all except ?

a) An autonomic nerve

b) Parasympathetic outflow

c) Arise from ventral rami of S2S3S4

d) Joins superior hypogastric plexus

Correct Answer - D

Pelvic splanchnic nerves (nervi erigentes)

- The nervi erigentes represent the sacral outflow of parasympathetic system and arise from ventral rami of S2 S3 S4.
- They join the right and left hypogastric nerves to form the *inferior hypogastric plexus* and are distributed to pelvic organs.
- Thus distribution of pelvic splanchnic nerve is same as of inferior hypogastric plexus.

241. Middle piece of sperm contains ?

a) Golgi apparatus

b) Mitochondria

c) Lysosome

d) Ribosome

Correct Answer - B
Ans. is 'b' i.e., Mitochondria

242. Which of the following is Climber's muscle ?

a) Serratus anterior

b) Lattissimus Dorsi

c) Rhomboidus major

d) Subscapularis

Correct Answer - B

Ans. is 'b' i.e., Lattissimus Dorsi

Lattissimus Dorsi is sometimes referred as the '*Climber's muscles*' as it comes in visible action in climbing up the trees, so also in swimming and rowing.

243. Which of the following is multipennate muscle ?

a) FPL

b) EPL

c) Deltoid

d) FHL

Correct Answer - C

Fascicular architecture of skeletal muscle

The major types of arrangement of muscle fibers or fasciculi are :-

1) Parallel fasciculi

The muscle fibers or fasciculi are parallel to line of muscle pull.

These muscles contract over a great distance (*have maximum range of movement*) and have good endurance.

Convergent fasciculi

- The muscle fibers or fasciculi converge at the insertion point to maximize contraction. Examples are :?

i) *Triangular* : Adductor longus

ii) *Fan-shaped* : Temporalis

3) **Spiral or twisted fasciculi**

- Muscle fibers are twisted or spiraled, e.g. trapezius, latissimus dorsi, pectoralis major, supinator.

4) **Cruciate muscle**

- Muscle fibers or fasciculi are arranged in superficial and deep planes and crossed 'X', e.g. sternocleidomastoid, masseter, adductor magnus.

5) **Sphincter fasciculi**

- Muscle fibers or fasciculi surround an opening or orifice, e.g. orbicularis oculi, orbicularis oris.

6) **Pennate fasciculi**

- Fibers run obliquely to the line of pull, so that muscle looks like the **feather** .

244. Spleen is derived from ?

a) Ventral mesogastrium

b) Dorsal mesogastrium

c) Septum transversorium

d) Allantois

Correct Answer - B
Dorsal mesogastrium

245. Uterus is derived from ?

a) Mesonephric duct

b) Urogenital sinus

c) Mesonephric tubule

d) Paramesonephric duct

Correct Answer - D
Paramesonephric duct

246. Stomach bed is formed by all except ?

a) Pancreas

b) Right kidney

c) Splenic artery

d) Diaphragm

Correct Answer - B

The posterior surface of stomach is related to structures forming the stomach bed, *all of which are separated from stomach by the cavity of the lesser sac*. These structures forming stomach bed are :-

- i. *Diaphragm,*
- i. *Pancreas (body)*
- i. *Splenic artery*
- /i. *Left kidney*
- /i. *Transverse colon*
- i. *Left suprarenal (adrenal) gland*
- i. *Splenic flexure of colon*
- Sometimes spleen is also included in stomach bed, but it is separated from stomach by greater sac (not lesser sac).

247. SA node is located in ?

a) Triangle of Koch's

b) In crista terminalis

c) In membranous part of interventricular septum

d) Upper part of interatrial septum

Correct Answer - B
In crista terminalis

248. Angle of anteversion of uterus is between ?

a) Long axis of uterus and cervix

b) Long axis of cervix and vagina

c) Long axis of uterus and vagina

d) None of the above

Correct Answer - C

Long axis of uterus and vagina

The normal position of the uterus is one of the *anteflexion* and *anteversion*, i.e. the fundus and upper part of the body bent forward in relation to the long axis of the cervix (*angle of anteflexion: normal 125°*, while the organ thus leans forward as a whole from the vagina (*angle of anteversion: normal 90°*)).

249. Cell lining of small intestine ?

a) Simple squamous

b) Stratified squamous

c) Simple columnar

d) Stratified columnar

Correct Answer - C

Simple columnar epithelium : It is made up of tall columnar cells. Simple columnar cells may be :

*i) Simple columnar epithelium (without cilia and microvilli) : Lining of stomach, large intestine, **collecting duct** and **cervical canal**.*

ii) Columnar epithelium with striated border (regularly arranged microvilli) : Lining of small intestine.

*iii) Columnar epithelium with brush border (irregularly placed microvilli) : **Lining of gall bladder**.*

*iv) Ciliated columnar epithelium (presence of cilia) : Lining of **uterus**, **fallopion tube**, eustachian tube, tympanic cavity and *central canal of spinal cord and ventricles*.*

250. Difference between large and small intestine is that small intestine has ?

a) Appendices epiploicae

b) Sacculaton

c) Taeniae coli

d) Intestinal vili

Correct Answer - D
Intestinal vili

251. Which border of scapula is not palpable ?

a) Medial

b) Lateral

c) Inferior

d) Superior

Correct Answer - D

"The medial border, inferior angle and part of the lateral border of scapula can be palpated on a patient as can the spine and acromion. The superior border and angle of the scapula are deep to soft tissue and are not readily palpable"

252. Not true about superior vena cava

a) Opens into right ventricle

b) Enters the heart at level of 3rd costal

c) Pierces paricardium at 2nd costal cartilage

d) Receives azygos vein behind sternal angle

Correct Answer - A

SVC opens in to right atrium (not right ventricle).

Superior vena-cava

- SVC collects blood from the upper half of the body and drains into the right atrium. It is formed by the union of two brachiocephalic veins at the level of lower border of 1st right costal cartilage. It passes vertically downwards behind the right border of sternum and *piercing the pericardium* at the level of the *second costal cartilage*, enters the upper border of the right atrium to end in the upper and posterior part of sinus venorum at the lower border of third right costal cartilage (opposite **T₅ vertebra**).
- **Superior vena cava :- Has no valve**
- Behind the sternal angle (T₄ vertebral level), SVC receives the azygos vein.
- SVC is divided into two parts -
 - i) Upper half (extrapericardial)
 - ii) Lower half (intrapericardial)

253. True about Falx cerebri ?

a) Separates cerebellum from occipital lobe

b) Contains straight sinus

c) Separates two cerebellar hemispheres

d) Contains occipital sinus

Correct Answer - B

Dura mater is the *toughest and thickest membrane* covering the brain. It is divisible into *outer endosteal layer or endocranium* (covering inner surface of skull bones) *and inner meningeal layer*. Inner meningeal layer is folded on itself at places dividing the cranial cavity into intercommunicating compartments which lodge different parts of brain :-

i) Falx cerebri : It is a large *sickle shaped* fold projecting into median longitudinal fissure between two cerebral hemisphere. It contains *superior sagittal sinus* (along lower concave free margin), and *straight sinus* (along line of attachment of falx cerebri to tentorium cerebelli).

ii) Tentorium cerebelli

iii) Falx cerebelli

iv) Diaphragma sellae

254. Main inspiratory muscle is ?

a) Lattissimus dorsi

b) Transversus thoracis

c) Serratus anterior

d) Diaphragm

Correct Answer - D

Respiratory muscles

Inspiratory muscles

1. *During quiet breathing* : Diaphragm (most important), external intercostal and interchondral part of internal intercostal.

2. *During forced inspiration* : Sternocleidomastoid, serratus anterior, serratus posterior superior, pectoralis major and minor, erector spinae, scaleni and levator costarum.

Expiratory muscles

1. *During quiet breathing* : Passive process due to passive recoil of the lungs and thoracic wall.

2. *During forced expiration* : Internal intercostal, innermost intercostal, transversus thoracic, serratus posterior inferior, subcostalis, *lattissimus dorsi* and abdominal muscles (rectus abdominis, internal and external oblique and transversus abdominis).

**255. Middle meningeal artery passes through
?**

a) Foramen ovale

b) Foramen lacerum

c) Foramen rotundum

d) Foramen spinosum

Correct Answer - D
Foramen spinosum

256. Origin of PCL- Posterior cruciate ligament

a) Posterior part of intercondylar area of tibia

b) Anterior part of intercondylar area of tibia

c) Medial part of medial femoral condyle

d) Lateral part of medial femoral condyle

Correct Answer - A

Posterior cruciate ligament (PCL)

- PCL begins *from posterior part of intercondylar area of tibia and runs upwards, forwards and medially to attach the anterior part of the lateral surface of medial condyle of femur.*
- PCL is *extrasynovial but intracapsular, i.e. lies between synovium and capsule of the knee joint.*
- It provides antero-posterior stability and *prevents posterior gliding of tibia on femur.*
- It is *taut in flexion.*
- Blood supply of cruciate (anterior & posterior) ligaments is from :-
 1. *Middle genicular artery (major supply).*
 2. *Inferior genicular (medial & lateral) artery (less important).*
 3. *Nerve supply of cruciate ligaments (ACL & PCL) is from posterior articular branch of tibial nerve.*

257. Pes anserinus includes following three muscles except

a) Semitendinosus

b) Semimembrinosus

c) Gracilis

d) Sartorius

Correct Answer - B

Semimembrinosus

Guy ropes or pes anserinus represent three muscles inserted into anteromedial surface of proximal tibia, one muscle from each compartment of thigh :?

i) Sartorius (from anterior compartment of thigh).

ii) Gracilis (from medial compartment of thigh).

iii) Semitendinosus (from posterior compartment of thigh).

258. Which of the following is not involved in formation of perineal body ?

a) Superficial transverse perenei

b) Deep transverse perenei

c) Bulbocavernosus

d) Levator ani

Correct Answer - A

Ans. is 'a' i.e., Superficial transverse perenei

Thyroid gland is the *largest endocrine gland* situated in front and sides of lower part of neck opposite C5-T4 vertebrae. The weight of thyroid gland is approximately *25 gm*. The gland is made of :-

i) Right and left lobes

ii) Isthmus

iii) Pyramidal lobe

The gland lies against vertebrae C5 to T1. Each lobe extends from the middle of thyroid cartilage to the 4th or 5th tracheal ring. The isthmus lies against the 2nd and 3rd tracheal rings.

259. Structure which lies outside the femoral sheath

a) Femoral artery

b) Femoral nerve

c) Femoral vein

d) Genitofemoral nerve

Correct Answer - B

Femoral nerve

Femoral sheath

Femoral sheath is a funnel shaped fascial prolongation around proximal part of femoral vessels, situated in the femoral triangle, below the inguinal ligament. *It is 3-4 cm long.* It is formed by fascia iliaca.

Femoral sheath is divided into 3 separate fascial compartments by septa :?

i) Lateral compartment :- It contains **femoral artery** and **femoral branch of genitofemoral nerve.**

ii) Intermediate compartment :- Femoral vein.

iii) Medial compartment (femoral canal) :- It is conical in shape, wider above and narrow below. The wider upper opening is known as **femoral ring**, which is potentially a *weak point* in lower abdomen and is the site for *femoral hernia*. *Femoral ring is bounded :*

Anteriorly by inguinal ligament, medially by lacunar ligament, posteriorly by pectineus with its covering fascia, and laterally by septum separating it from femoral vein. Femoral canal contains lymph node of cloquet or Rosenmuller and lymphatics.

260. Rotator cuff is/are formed by all except

a) Supraspinatus

b) Infraspinatus

c) Teres minor

d) Teres major

Correct Answer - D

Teres major

Rotator cuff (Musculotendinous cuff) is formed by blending of tendons of supraspinatus (superiorly); *infraspinatus and teres minor* (posteriorly) and *subscapularis* (anteriorly).

261. Brunners glands are seen in ?

a) Jejunum

b) Upper duodenum

c) Lower duodenum

d) Appendix

Correct Answer - B

Upper duodenum

The presence of mucous duodenal (Brunner's) glands in the submucosa is *indicative of upper duodenum*. These submucosal glands are absent in the jejunum, ileum and the entire large intestine.

262. Which of the following nerve does not have root valve C5, C6,C7

a) Lateral pectoral nerve

b) Musculocutaneous nerve

c) Lateral root of median nerve

d) Ulnar nerve

Correct Answer - D

Ulnar nerve does not have root valve C5, C6,C7 .

263. Mandible is derived from ?

a) Meckle's cartilage

b) Ritchers cartilage

c) 4th Pharyngeal pouch

d) 6th Pharyngeal pouch

Correct Answer - A

Ans. is 'a' i.e., Meckle's cartilage

Each half of the mandible ossifies from only one *centre* which appears at about the *6th week* of intrauterine life in the mesenchymal *sheath of Meckels cartilage* near the future mental foramen.

Meckle's cartilage is the skeletal element of first *pharyngeal arch*.

264.

An intern while doing venesection at lower limb could injure ?

a) Sural nerve

b) Saphenous nerve

c) Common peroneal nerve

d) Tibial nerve

Correct Answer - B

Ans. is 'b' i.e., Saphenous nerve

Venesection of lower limb is usually done in great saphenous vein, which is accompanied by saphenous nerve.

265.

Secretory part of kidney develops from ?

- a) Ureteric bud
- b) Mesonephros
- c) Blastema
- d) Paramesonephric duct

Correct Answer - C

Ans. is 'c' i.e., Blastema

Development of kidney

Ureteric bud (mesonephros) arise from mesonephric duct and gives rise to *collecting system* of kidney (renal pelvis, major and minor calyces, *collecting tubule*) and *ureter*.

Metanephric mesoderm (blastema or metanephros) arise from *nephrogenic cord* which in turn is derived from intermediate mesoderm. It gives rise to *excretory unit (nephron)*, i.e. glomeruli, PCT, Loop of henle and DCT.

266. True about saphenous opening ?

a) Saphenous vein passes above this opening

b) Situated above and lateral to pubic tubercle

c) Covered by cribriform fascia

d) Opening in scarpa's fascia

Correct Answer - C

Ans. is 'c' i.e., Covered by cribriform fascia

Saphenous opening

- This is an oval opening in the fascia lata.
- The centre of the opening is 4 cm below and 4 cm lateral to the pubic tubercle.
- It is about 2.5 cm long and 2 cm broad with its long axis directed downwards and laterally.
- The opening has a sharp crescentic lateral margin or falciform margin which lies in front of the femoral sheath.
- The medial well define margin of the opening lies at a deeper level.
- It is formed by the fascia overlying the pectineus. The fascia passes behind the femoral sheath.
- The saphenous opening is closed by the *cribriform fascia* formed by modification of superficial fascia which covers the opening.

267. Triangular space between clitoris and hymen ?

a) Fourchette

b) Fossa navicularis

c) Vestibule

d) Labia minora

Correct Answer - C

Ans. is 'c' i.e., Vestibule

Female genitals :?

- The labia majora are the two elongated folds of skin projecting downwards and backwards from the mons veneris.
- The *labia minora* are two thin folds of skin just within labia majora.
- The lower portions of labia called fourchette.
- The depression between fourchette and the vaginal orifice is called fossa navicularis.
- The Vestibule is the triangular surface which *extends from clitoris (above) to hymen (below) and labia minora (laterally)*.
- Urethral opening is 2.5 cm behind the clitoris, and immediately in front of vaginal opening.
- Vulva includes mons veneris, clitoris, labia majora, labia minora, vestibule, hymen and urethral opening.

268. Cell lining of common bile duct is ?

a) Stritified Columnar

b) Stratified squamous

c) Simple cuboidal

d) Simple columnar

Correct Answer - D

Ans. is 'd' i.e., Simple columnar

Gall bladder and common bile ducts are lined by simple columnar epithelium.

269. Length of human intestine is about ?

a) 5 meter

b) 8 meter

c) 12 meter

d) 15 meter

Correct Answer - B

Ans. is 'b' i.e., 8 meter

Length of human intestine is 7.5 meter to 8.5 meter :-

Small intestine → 6 to 7 meter

Large intestine → 1.5 meter

270. Which of the following is present in cartilage but not in bone tissue ?

a) Type 1 collagen

b) Blood

c) Nerves

d) Chondroitin sulfate

Correct Answer - D

Ans. is 'd' i.e., Chondroitin sulfate

271. Space of Disse contains all except ?

a) Microvilli

b) Blood plasma

c) Kupffer's cell

d) None of the above

Correct Answer - C

Ans. is 'c' i.e., Kupffer's cell

The space of Disse (Perisinusoidal space) is a space between hepatocytes and hepatic sinusoids.

The exchange of substance between hepatocytes and blood takes place in the space of Disse.

Microvilli of hepatocytes extend into this space, increasing surface area for absorption.

Major constituent of space of Disse is blood plasma.

272. True about vertebral artery ?

a) A branch of thyrocervical trunk

b) Enters skull through foramen magnum

c) Unite to form posterior cerebral artery

d) A small artery

Correct Answer - B

Ans. is 'b' i.e., Enters skull through foramen magnum

Vertebral artery

- It is the largest branch of subclavian artery.
- Vertebral artery traverses through *vertebral triangle*, *foramina transversaria of upper six cervical vertebrae*, suboccipital triangle, posterior atlanto-occipital membrane, vertebral canal, pierce duramater and arachnoid (Subarachnoid) and passes through foramen magnum to enter *posterior cranial fossa*. It gives following branches:-
 1. *Cervical branches* :- Spinal branches, muscular branches (to suboccipital muscle).
 2. *Cranial branches* :- Posterior inferior cerebellar artery, medullary artery, meningeal branches, anterior spinal artery, posterior spinal artery and both vertebral arteries unite to form basilar artery.

273. Crura of penis is supplied by ?

a) Dorsal artery of penis

b) Deep artery of penis

c) External pudendal artery

d) Obturator artery

Correct Answer - B

Ans. is 'b' i.e., Deep artery of penis

Internal pudendal artery on each side enters the deep perineal pouch and passes forward, giving rise to :-

i) Artery to the bulb of penis.

ii) Arteries to crura of the penis (deep artery of penis).

iii) Dorsal artery of penis which supplies the skin and fascia of penis.

274. Sweat glands are which types of gland ?

a) Simple tubular

b) Simple coiled tubular

c) Compound tubular

d) Compound acinar

Correct Answer - B

Ans. is 'b' i.e., Simple coiled tubular

275. Lateral border of ischioanal fossa is formed by?

a) Gluteus maximus

b) Perineal membrane

c) Pelvic diaphragm

d) Obturator internus

Correct Answer - D

Ans. is 'd' i.e., Obturator internus

Boundries of ischioanal (ischioanal) fossa are :-

i) Anteriorly :- Posterior border of perineal membrane .

ii) Posteriorly :- Gluteus maximus muscle, sacrotuberous ligament.

iii) Laterally :- Ischial tuberosity and obturator internus.

iv) Medially :- Sphincter ani externus (external anal sphincter) and pelvic diaphragm (levator ani).

276. Muscle attached to coracoid process ?

a) Pectoralis major

b) Long head of triceps

c) Medial head of triceps

d) Short head of biceps

Correct Answer - D

Ans. is 'd' i.e., Short head of biceps

Tip of the coracoid process gives origin to coracobrachialis (medially) and short head of the biceps. The upper surface receives insertion of pectoralis minor.

277. Feature of epithelium of anal canal ?

a) Upper part is lined by stratified columnar epithelium

b) Upper part contains anal columns of morgagni

c) Middle part is below Hilton's line

d) Middle part contains sweat and sebaceous glands

Correct Answer - B

Ans. is '**b**' i.e., Upper part contains anal columns of morgagni
The interior of anal canal is divided by *pectinate line* and *Hilton's white line* into three parts.

1) Upper part (mucous part)

- It is upper 15 mm part of anal canal and extends upto pectinate line. It is lined by mucous membrane which is *simple columnar*. Mucosa shows 6-10 longitudinal folds called anal columns of Morgagni. Lower ends of these folds are united by short transverse folds, *anal valves*. Line of attachment of anal valve is known as pectinate line or dentate line. Slight depression above each anal valve is known as *anal sinus*.

2) Middle part (transitional zone or pecten)

- This area is 15 mm in extent and intervenes *between pectinate (dentate) line and Hilton's white line*. It is lined by *non-keratinized stratified squamous epithelium* without sebaceous and sweat glands.

3) Lower part (cutaneous) part

- It is about 8 mm in extent and is *lined by true skin*, i.e. *stratified squamous keratinizing epithelium* with sebaceous and sweat glands.

278. Superior gluteal nerve does not supply ?

a) Tensor fasciae latae

b) Gluteus medius

c) Gluteus minimus

d) Gluteus maximus

Correct Answer - D

Ans. is 'd' i.e., Gluteus maximus

Nerve supplying muscles of gluteal region are :-

i) Inferior gluteal nerve : Gluteus maximus.

ii) Superior gluteal nerve : Gluteus medius and minimus.

iii) Nerve to piriformis : Piriformis

iv) Nerve to obturator internus : Obturator internus, Gemellus superior.

v) Nerve to quadratus femoris : Quadratus femoris, Gemellus inferior.

Tensor fasciae latae is supplied by superior gluteal nerve.

279. Muscle of fascial expression, which is not supplied by facial nerve ?

a) Orbicularis oris

b) Orbicularis oculi

c) Frontalis

d) Levator palpebrae superioris

Correct Answer - D

Ans. is 'd' i.e., Levator palpebrae superioris

Nerve supply of face

- Each half of the face is supplied by *fourteen nerves*, one is motor and the rest are sensory.
- Motor supply is derived from *facial (7th) nerve* which supplies all facial muscles except levator palpebrae superioris, which is supplied by sympathetic fibers and 3rd cranial nerve.
- *Eleven sensory nerves* are derived from branches of *trigeminal (5th) nerve* and only *two sensory* are derived from *great auricular nerve* and *transverse (anterior) cutaneous nerve of neck*.

280. Muscle of Arm with additional supinator action?

a) Brachialis

b) Biceps

c) Coracobrachialis

d) Triceps

Correct Answer - B
Ans. is 'b' i.e., Biceps

281. Dilator pupillae develops from ?

a) Neural ectoderm

b) Surface ectoderm

c) Mesoderm

d) Neural crest

Correct Answer - A
Ans. is 'a' i.e., Neural ectoderm

282. Hartman's pouch is seen in ?

a) Liver

b) Bile duct

c) Pancreas

d) Gall bladder

Correct Answer - D

Ans. is 'd' i.e., Gall bladder

- Gall bladder is a pear-shaped hollow viscus situated in a non-peritoneal fossa on the undersurface of right lobe of liver.
- It is 7-10 cm long, 3 cm broad and has a capacity of 30-50 ml.
- Gall bladder is divided into (from below upwards) :- *fundus, body and neck*.
- Fundus projects beyond the inferior border of liver.
- Body lies in the fossa for gallbladder on the undersurface of right lobe of liver.
- Neck is `S' shaped and extends from the body to cystic duct, i.e. neck becomes continuous with cystic duct.
- From the neck, a small diverticulum known as *Hartman's pouch* projects downwards and backwards towards the duodenum.
- The wall of gall bladder is made up of mucous membrane, a fibromuscular coat and a serous layer that covers part of organ.
- The mucosa is noted for outpouchings extending into and through muscular fibers, called as Rokitansky-Aschoff sinuses.

283. Arteria pancreatic magna is a branch of which artery ?

a) Left gastric

b) Right gastric

c) Common hepatic

d) Splenic

Correct Answer - D

Ans. is 'd' i.e., Splenic

Branches of coeliac trunk

The coeliac trunk is only about 1.25 cm long and it ends by divided into its three terminal branches :?

1) Left gastric artery :- It is the *smallest branch of coeliac trunk*. It ends by anastomosing with right gastric artery. It gives off :

a) *Two or three esophageal branches.*

b) *Number of gastric branches.*

2) Common hepatic artery :- It runs to the right behind lesser sac and enters the *free right border of lesser omentum* and then run upwards as proper hepatic artery, in front of portal vein and to the left of bile duct. After reaching the porta hepatis it terminates by dividing into *right and left hepatic branches*. It gives of following branches :

a) *Gastroduodenal artery* :- It terminates by dividing into right gastroepiploic artery and superior pancreaticoduodenal artery.

b) *Right gastric artery.*

c) *Cystic artery* :- It is a branch of right hepatic artery.

3) Splenic artery :- It is the *largest branch of coeliac trunk*. It runs horizontally to the left along upper border of pancreas and has tortuous course. It crosses left suprarenal gland and left kidney to

enter the lienorenal ligament through which it reaches the hilum of spleen where it divides into 5-7 splenic (hilar) branches. It gives off :

- a) *Numerous pancreatic branches* :- These supply body and tail of pancreas. One of the pancreatic branches is large and is called *arteria pancreatic magna*. Another large branch is called *arteria caudae pancreatis*.
- b) *Short gastric arteries* :- Run in gastrosplenic ligament and supply the fundus of stomach.
- c) *Left gastroepiploic artery* :- It anastomoses with right gastroepiploic artery and supplies stomach and *greater omentum*.
- d) *Posterior gastric artery* :- It is an inconsistent branch and supplies posterior body and fundus of stomach.

284. Not associated with damage during submandibular excision ?

a) Lingual

b) Hypoglossal

c) Gossopharyngeal

d) Mandibular branch of facial

Correct Answer - C

Ans. is 'c' i.e., Glossopharyngeal

Cervical branch of facial nerve is related to inferior surface of submandibular gland. Lingual nerve and hypoglossal nerve are related to submandibular gland. Thus, these nerve can be damaged during submandibular gland excision.

285. Posterior border of ovary is ?

- a) Attached to suspensory ligament
- b) Attached to broad ligament
- c) Attached to infundibulopelvic ligament
- d) Free of ligament attachment

Correct Answer - D

Ans. is 'd' i.e., Free of ligament attachment

OVARY

The ovaries are *female gonads*. Each ovary lies in the ovarian fossa on the lateral pelvic wall which is bound *anteriorly* by obliterated umbilical artery and *posteriorly* by ureter and *internal iliac artery*.

Each ovary has two poles (upper and lower), two borders (anterior and posterior) and two surfaces (medial and lateral).

Upper pole (tubal end) is related to ovarian fimbria of fallopian tube and external iliac artery. *Suspensory ligament of ovary (infundibulopelvic ligament)* connects it with pelvic brim.

Lower pole (uterine end) is connected with lateral angle of uterus by *ligament of the ovary*, just posteroinferior to the attachment of fallopian tube.

Lateral surface is related to ovarian fossa and is covered with peritoneum which separates it from Obturator vessels and nerve.

Medial surface is related to fallopian tube and is separated by a peritoneal recess, called ovarian bursa.

Anterior border (mesovarian border) is straight and related to fallopian tube and obliterated umbilical artery. It is attached to posterior surface of broad ligament of uterus by mesovarium and forms the *hilus of ovary*.

Posterior border (free border) is convex and is related to fallopian

tube and ureter.

286. Rathke's pouch is related to the development of ?

a) Posterior pituitary

b) Neurohypophysis

c) Adenohypophysis

d) None of the above

Correct Answer - C

Ans. is 'c' i.e., Adenohypophysis

PITUITARY GLAND (HYPOPHYSIS CEREBRI)

Pituitary gland lies within hypophyseal/pituitary fossa or sella turcica of sphenoid bone which is roofed by diaphragm sellae. It is suspended from tuber cinereum of hypothalamus by infundibulum (pituitary stalk). It is related anterosuperiorly to optic chiasma, laterally to cavernous sinus and inferiorly to sphenoid air sinuses in the body of sphenoid. Pituitary gland is oval in shape, measures 8 x12 mm, and weighs about 500 mg. Pituitary gland has two main subdivisions:- (i) *Adenohypophysis (anterior lobe)*, and (ii) *Neurohypophysis (posterior lobe)*.

Adenohypophysis (anterior lobe) include :- (i) pars anterior or pars distalis or pars glandularis or anterior lobe proper, (ii) pars intermedia (intermediate lobe); and (iii) tuberal lobe (pars tuberalis). It develops from an upward growth (Rathke's pouch) from the ectodermal roof of stomodeum.

Neurohypophysis (posterior lobe) include (i) pars posterior or pars nervosa or neural lobe or posterior lobe proper; (ii) infundibulum (infundibular stem); and (iii) median eminence. It develops from a downgrowth from the 3rd ventricle/diencephalon (neuroectoderm) called infundibulum.

Anterior lobe contains many hormone secreting cells: chromophils (acidophils, basophils), chromophobes and folliculostellate cells. Posterior pituitary contain neuroglia like pituicytes which do not secrete any hormone. The posterior pituitary hormones (ADH and oxytocin) are synthesized in hypothalamus and transported to posterior lobe by hypothalamohypophyseal nerve fiber tract and stored in the axon terminals of neurohypophysis in Herring bodies before their release.

287. Not true about right atrium ?

a) Posterior part is smooth

b) Anterior part is derived from absorption of right horn of sinus venosus

c) Fossa ovalis represent remnant of foramen ovale

d) Anterior and posterior parts are divided by Crista terminalis

Correct Answer - B

Ans. is 'b' i.e., Anterior part is derived from absorption of right horn of sinus venosus

Sinus venarum (posterior part of right atrium) is derived from absorption of right horn of sinus venosus (not anterior part).

Right atrium

It has *thinnest walls* of the four chambers. It is divided by crista terminalis into two parts :-

i) Rough anterior part or atrium proper (pectinate part), including auricle.

It is *derived from right half of primitive atrial chamber*. There is a series of transverse muscular ridges called *musculi pectinate* which are attached to crista terminalis and gives appearance like "*teeth of a comb*". SA node is situated in the upper part of crista terminalis. Auricle lies in the superomedial portion.

ii) Posterior smooth part or sinus venosum.

It is derived from *absorption of right horn of sinus venosus*. It has openings of :-

1) *Superior vena cava* :- Has no valve.

2) *Inferior vena cava* :- Orifice is guarded by a rudimentary valve of IVC (*Eustachian valve*) derived from embryonic right venous valve, which directs the blood from IVC towards *foramen ovale* in fetal life.

This valve is nonfunctional in adults.

3) *Coronary sinus* :- Orifice lies between tricuspid orifice and IVC orifice. It is guarded by a functional semilunar valve (thebesian valve). Thebesian valve develops from right venous valve.

4) *Venae cardis minimae (thebesian veins)*:- Open through foramina venorum minimarum.

5) *Anterior cardiac vein*

6) *Right marginal vein* :- Sometimes it may open into coronary sinus (not in right atrium).

iii) Interatrial septal region

Interatrial septum develops from approximation of embryonic septum primum and septum secundum. Features on right atrial side are :

1) *Fossa ovalis* :- Oval shaped depression lying above the level of IVC opening in the interatrial septum. It is the embryologic remnant of foramen ovale, which connects right atrium to left atrium in embryonic life. Floor of the fossa ovalis is formed by septum primum.

2) *Limbus fossa ovalis (Annulus ovalis)* :- It is thickened rim present above the fossa ovalis. It represents the lower free margin of septum secundum.

3) *Triangle of Koch* :- It is a triangular region in the lower part of interatrial septum which contains AV node. It is bounded above by tendon of Todaro below by base of septal leaflet of tricuspid valve and anteriorly (base) by orifices of coronary sinus.

Immediately above the membranous septum, the septal region shows a slight bulge known as torus aorticus, produced by right posterior (non-coronary) aortic sinus (of valsalva).

288. Lymphatic drainage of Vulva is into ?

a) Obturator nodes

b) Internal iliac nodes

c) Superficial inguinal nodes

d) Paraaortic nodes

Correct Answer - C

Ans. is 'c' i.e., Superficial inguinal nodes

Lymphatics of Vulva drain primarily into superficial inguinal lymph nodes and subsequently to deep inguinal and external iliac nodes.

Lymphatics of Clitoris primarily drain into deep inguinal nodes.

289. Lower border of pharynx is at the level of (Extent of pharynx is upto) ?

a) C2

b) C3

c) C4

d) C6

Correct Answer - D

Ans. is 'd' i.e., C6

Pharynx is a musculomembranous tube that extends from the *base of skull to the level of the sixth cervical vertebra*, where it is continuous with esophagus. Pharynx is subdivided into :?

- 1) Nasopharynx :- Part of the pharynx above the soft palate, i.e. from the base of skull to the soft palate?
- 2) Oropharynx :- Extends from the soft palate superiorly to the level of hyoid inferiorly.
- 3) Hypopharynx :- The hypopharynx includes that portion of the pharynx below the level of the hyoid.

290.

Anal valve is found in which part of anal canal ?

a) Upper

b) Middle

c) Lower

d) At anus

Correct Answer - A
Ans. is 'a' i.e., Upper

291. Action of anconeus ?

a) Mild pronation

b) Flexion

c) Supination

d) Extention

Correct Answer - D
Ans. is 'd' i.e., Extention

292. Which muscle is inserted into the floor of the intertubercular sulcus of the humerus?

a) Latissimus dorsi

b) Teres major

c) Pectoralis major

d) Deltoid

Correct Answer - A

Ans. is 'a' i.e., Latissimus dorsi

The shaft of humerus is cylindrical in the upper half and triangular on cross-section in the lower half. The upper part has intertubercular sulcus (bicipital groove) anteriorly. Bicipital groove contains long head of biceps with its synovial sheath and an ascending branch of anterior circumflex humeral artery. Middle third of posterior surface of shaft of the humerus has a spiral groove (radial groove) which contains radial nerve and *profunda brachii* vessels.

Attachment to shafts are ?

- i) Insertions of pectoralis major (on lateral lip of bicipital groove), latissimus dorsi (on floor of bicipital groove), teres major (on deltoid tuberosity) and coracobrachialis (medially on mid shaft).
- ii) Origin of brachialis (anterior surface); Lateral and medial head of triceps (posterior surface); pronator teres (from medial supracondylar ridge); brachioradialis (from lateral supracondylar ridge) and ECRL (from lateral supracondylar ridge).

293. The fascia from rectum to posterior pelvic wall is?

a) Fascia of waldeyer

b) Fascia of Denonviller

c) Scarpa's fascia

d) Colle's fascia

Correct Answer - A

Ans. is 'a' i.e., Fascia of Waldeyer

Posteriorly rectum is related to sacrum, Coccyx, sacral nerves, median sacral artery and sacral veins.

- A fascia, known as Waldeyer's fascia, Separates the rectum from these structures and contains the plexus of veins draining the rectum.
- It is also called as presacral fascia.

About other options

- Scarpa's fascia is deep membranous layer of superficial fascia of anterior abdominal wall.
- Colle's fascia is membranous layer of superficial fascia of perineum.
- Fascia of Denonviller separates rectum from prostate.

294. Ventral pancreatic duct give rise to ?

a) Body

b) Tail

c) Neck

d) Uncinate process

Correct Answer - D

Ans. is 'd' i.e., Uncinate process

Development of pancreas

- Pancreas is developed from the two pancreatic buds.
 - i) *Dorsal pancreatic bud* :- It is larger and most of the pancreas is derived from it i.e. most of the head, and whole neck, body & tail.
 - ii) *Ventral pancreatic bud* :- It is smaller and forms lower part of the head of pancreas including uncinata process.
- During 7th week of development, the ventral and dorsal pancreatic buds fuse to form a single pancreatic mass.
- After the fusion of ventral and dorsal pancreatic buds, their ducts develop cross communications. Final duct system is formed as below ?
 - i) *Main pancreatic duct (Duct of wirsung)* is formed by the *duct of ventral bud, distal part of duct of dorsal bud and an oblique communication between the two*. The main pancreatic duct join the bile duct to form hepatopancreatic ampulla that enters th 2nd part of duodenum at major duodenal papilla.
 - ii) *Accessory pancreatic duct* is formed by the proximal part of the duct of dorsal bud. It opens into 2nd part of duodenum at *minor duodenal papilla*, 2 cm proximal (cranial) to major duodenal papilla.

Anomalies of pancreatic development may be:

1. *Annular pancreas* :- Two components of the ventral bud fail to

fuse and grow in opposite direction around the duodenum and meet the dorsal pancreatic duct.

2. *Pancreatic divisum (divided pancreas)* :- Ventral and dorsal buds fail to fuse with each other. It is the most common congenital anomaly of pancreas.

3. *Inversion of pancreatic duct* :- The main pancreatic duct is formed by the duct of dorsal bud, i.e. accessory duct is larger than the main duct and the main drainage of pancreas is through the minor duodenal papilla.

4. *Accessory pancreatic tissue* :- May be found in ?

- i) Wall of stomach, duodenum, jejunum or ileum.
- ii) Meckel's diverticulum.

295. All are derived from neural crest except ?

a) Adrenal medulla

b) Pigment cell in skin

c) Corneal stroma

d) Retinal pigmented epithelium

Correct Answer - D

Ans. is 'd' i.e., Retinal pigmented epithelium

Derivatives of neuroectoderm

i) From neural tube : CNS (brain, spinal cord), astrocytes, oligodendrocytes, ependymal cells, retina, pineal gland, neurohypophysis (posterior pituitary), all cranial and spinal motor nerves.

ii) From neural crest : Neural crest derivatives are :?

a) Neural derivatives

- Sensory neurons of 5th, 7th, 8th, 9th, 10th cranial nerve ganglia (trigeminal, geniculate, sphenopalatine, submandibular, cochlear, vestibular, otic and vagal parasympathetic ganglia).
- Sensory neurons of spinal dorsal root ganglia.
- Sympathetic chain ganglia and plexus (celiac/preaortic/renal ganglia, enteric plexus in GIT, i.e. Auerbachs and Meissner's)
- Parasympathetic ganglia and plexus of GIT.
- Schwann cells of peripheral nerves, satellite cells of all ganglia.
- Adrenal medulla, chromaffin cells, para follicular C-cells of thyroid gland.
- Melanocytes and melanoblasts.

296. Sympathetic ganglion develops from ?

a) Surface ectoderm

b) Mesoderm

c) Neural crest

d) Mesenchymal neuroectoderm

Correct Answer - C
Ans. is 'c' i.e., Neural crest

297. Boundries of foramen of Winslow is formed by all except ?

a) IVC

b) Liver

c) 2nd part of duodenum

d) Suprarenal gland

Correct Answer - C

Ans. is 'c' i.e., 2nd part of duodenum

298. Watershed line in anal canal ?

a) Hilton's line

b) Pectinate line

c) Mucocutaneous junction

d) None

Correct Answer - B

Ans. is 'b' i.e., Pectinate line

Pectinate line forms the *water-shed line* of anal canal.

Area above pectinate line drains into internal iliac nodes and area below it drains into superficial inguinal nodes.

299. All nerves pass thorough greater sciatic notch except ?

a) Superior gluteal nerve

b) Inferior gluteal nerve

c) Sciatic nerve

d) Obturator nerve

Correct Answer - D
Ans. is 'd' i.e., Obturator nerve

300. Which of the following is not intracapsular ?

a) Coronoid fossa

b) Radial fossa

c) Olecranon fossa

d) Lateral epicondyle

Correct Answer - D

Ans. is 'd' i.e., Lateral epicondyle

The capsular ligament of the elbow joint is attached to the lower end along a line that reaches the upper limits of the radial and coronoid fossae anteriorly; and of the olecranon fossa posteriorly; so that these fossae lie within the joint cavity.

Medially, the line of attachment passes between the medial epicondyle and the trochlea.

On the lateral side, it passes between the lateral epicondyle and the capitulum.

301. True about Schwann cells ?

a) Part of central nervous system

b) Present only in myelinated nerve fibres

c) Form myelin sheath

d) Derived from surface ectoderm

Correct Answer - C

Ans. is 'c' i.e., Form myelin sheath

Shwann cells

- In peripheral nervous system (PNS), Schwann cells provide structural support to all nerve fibres. *Schwann cells* form a sheath around the axon and form the outermost layer of a nerve fiber, called *neurilemma*, also known as *sheath of Schwann* or *neurolemma*. Schwann cells is surrounded by a basal lamina (or external lamina).
- In some fibres, Schwann cells additionally form myelin sheath; these fibres are called *myelinated nerve fibres*. Those nerve fibres in which myelin sheath is not formed, that is Schwann cells only provide structural support, are *non-myelinated nerve fibres*.
- Schwann cells deposit concentric layers of myelin around the axon to form myelin sheath. In myelinated fibres, one Schwann cell covers only a short segment of the axon. The small part of the axon present in between two adjacent Schwann cells (the part that is devoid of myelin sheath) is called node of Ranvier.
- Myelin is a mixture of lipoproteins and acts as an insulator. Since myelin acts as an insulator, impulses are generated only at the nodes of Ranvier and this helps in faster conduction of the impulses. This is called *saltatory conduction*.
- Schwann cells are derived from neuroectoderm.

302. True about atrioventricular groove are all except ?

a) Contains left anterior descending coronary artery

b) Also called coronary sulcus

c) Contains right coronary artery

d) Contains circumflex branch of left coronary artery

Correct Answer - A

Ans. is 'a' i.e., Contains left anterior descending coronary artery

Grooves (sulci) of heart

A) Atrioventricular groove

- Atria are separated by ventricles by atrioventricular Sulcus (atrioventricular groove, also called coronary sulcus).
- It is divided into anterior and posterior parts. The right half of anterior part is large and lodges right coronary artery. Left half of anterior part is small and lodges circumflex branch of left coronary artery.

B) Interventricular grooves

- Right and left ventricles are separated by interventricular grooves.
- Anterior interventricular groove is nearer to left margin of heart and contains anterior interventricular artery (also called left anterior descending artery).
- Posterior interventricular groove is situated on diaphragmatic (inferior) surface. It contains posterior interventricular artery (continuation of RCA).

303. Which is not a content of inguinal canal ?

a) Spermatic cord

b) Ilioinguinal nerve

c) Genital branch of genitofemoral nerve

d) Inferior epigastric artery

Correct Answer - D

Ans. is 'd' i.e., Inferior epigastric artery

Contents of inguinal canal

- Spermatic cord in male or round ligament of uterus in female.
- Ilioinguinal nerve : It enters through the interval between external and internal oblique muscles.
- Genital branch of genitofemoral nerve is a constituent of spermatic cord.

304. Which of the following is not a branch of Arch of aorta ?

a) Branchiocephalic trunk

b) Left subclavian artery

c) Left common carotid artery

d) Right subclavian artery

Correct Answer - D

Ans. is 'd' i.e., Right subclavian artery

305. Medial longitudinal arch of the foot is maintained by all except ?

a) Peroneous longus

b) Tibialis posterior

c) Flexor digitorum longus

d) Plantar aponeurosis

Correct Answer - A

Ans. is 'a' i.e., Peroneous longus

The arches of the foot are well known features of the foot. There are two longitudinal arches, i.e. medial longitudinal arch and lateral longitudinal arch.

In addition there are two transverse arches, i.e. posterior transverse arch and an anterior transverse arch.

306. Action of tibialis anterior ?

a) Plantar flexion of foot

b) Adduction of foot

c) Inversion of foot

d) None of the above

Correct Answer - C

Ans. is 'c' i.e., Inversion of foot

307. Serratus anterior is supplied by ?

a) Thoracodorsal nerve

b) Axillary nerve

c) Musculocutaneous nerve

d) Nerve of bell

Correct Answer - D
Ans. is 'd' i.e., Nerve of bell

308. Gastrosplenic ligament is due to peritoneal reflection of which artery ?

a) Splenic artery

b) Short gastric artery

c) Pancreatic artery

d) Common hepatic artery

Correct Answer - B

Ans. is 'b' i.e., Short gastric artery

309. Spring ligament consists of all except ?

a) Plantar calcaneocuboid ligament

b) Plantar calcaneonavicular ligament

c) Medial calcaneonavicular ligament

d) Lateral calcaneonavicular ligament

Correct Answer - A

Ans. is 'a' i.e., Planter calcaneocuboid ligament

The spring ligament (Plantar calcaneonavicular ligament) is a group of ligaments which connect calcaneum to navicular.

It consists of :?

i) Superomedial ligament.

ii) *Medioplantar oblique ligament (medial or intermedial calcaneonavicular ligament).*

iii) *nferoplantar longitudinal ligament (Lateral calcaneonavicular ligament).*

The *spring ligament* or *plantar calcaneonavicular ligament* is powerful.

It is attached posteriorly to the anterior margin of the sustentaculum tali, and anteriorly to the plantar surface of the navicular bone between its tuberosity and articular margin.

The head of the talus rests directly on the upper surface of the ligament, which is covered by fibrocartilage.

The plantar surface of the ligament is supported by the tendon of tibialis posterior medially, and by the tendons of flexor hallucis longus and flexor digitorum longus, laterally.

310. ACL originates from ?

a) Posterior part of intercondylar area of tibia

b) Anterior part of intercondylar area of tibia

c) Medial part of medial femoral condyle

d) Lateral part of lateral femoral condyle

Correct Answer - B

Ans. is 'b' i.e., Anterior part of intercondylar area of tibia

Anterior cruciate ligament (ACL)

- ACL is one of the most important ligament of the knee joint.
- ACL begins *from anterior part of intercondylar area of tibia just behind the anterior horn of medial meniscus and runs upwards, backwards & laterally to attach the posterior part of medial surface of lateral condyle of femur.*
- ACL is *intrasynovial i.e.,* it lies inside the synovium.
- ACL also provides *proprioceptive function* of knee joint.
- ACL is *taut during extension.*

311. Neural crest cells give rise to all the dental structures except ?

a) Odontoblasts

b) Dentine

c) Enamel

d) Tooth pulp

Correct Answer - C

Ans. is 'c' i.e., Enamel

Teeth development

A) Neural crest derivatives (Derivatives of neuroectoderm)

- Mesenchymal cells (derived from neural crest) of dental papilla form :?

i) Odontoblasts which form Dentine

ii) Tooth pulp

B) Derivatives of surface ectoderm

- It gives rise to ameloblasts which form *enamel*.

312. Nucleus pulposus is derived from ?

a) Sclerotome

b) Myotome

c) Notochord

d) None

Correct Answer - C

Ans. is 'c' i.e., Notochord

Development of vertebral column

- The human nervous system develops from *neuroectoderm*.
- During development, behind the neuroectoderm lies the *mesoderm* (*paraxial mesoderm*) that *encloses the notochord* (a derivative of endoderm).
- This paraxial mesoderm give rise to *somites*.
- Somites further differentiated into
 - i. *Dermatomyotome* :- Give rise to skeletal muscles and dermis.
 - i. *Sclerotomes* :- Give rise to vertebral column.

Sclerotomes which surround notochord starts projecting posteriorly (dorsally) to surround neural tube and forms.
- *Ventral sclerotomes* :- Give rise to *vertebral body and annulus fibrosus*.
- *Lateral sclerotomes* :- Give rise to *vertebral arch (pedicle and lamina)*.
- *Dorsal sclerotomes* :- Give rise to spinous process.
- *The notochord forms the nucleus pulposus.*

313.

Second part of duodenum not related posteriorly to?

a) IVC

b) Psoas major

c) Bile duct

d) Renal artery

Correct Answer - C
Ans. is 'c' i.e., Bile duct

314. Which of the following does not form portal triad in liver

a) Hepatic artery

b) Hepatic vein

c) Bile duct

d) Portal vein

Correct Answer - B

Ans. is 'b' i.e., Hepatic vein

Histology of the Liver

- Liver is covered by Glisson's capsule.
- Liver is divided into hexagonal lobules oriented around the terminal tributaries of the hepatic vein (Terminal hepatic veins), i.e. Terminal hepatic vein is in the centre of the lobule and area around the hepatic vein is called centrilobular zone.
- At periphery of lobule, lies the portal tract containing hepatic artery, bile duct and portal vein. Area around portal tract is called periportal zone.
- These three structures (portal vein, hepatic artery and bile duct) form portal triad.
- Area between periportal zone and centrilobular zone is called midzonal area.
- All around the central vein are the major parenchymal cells, i.e. hepatocytes.
- Lobule contains *sinusoid (sinusoidal capillaries)* which have fenestrated *endothelium* covering the subendothelial space of Disse. This space contains stellate cell processes and hepatocellular microvilli.
- Other important cells of liver are *Kupffer cells*, which belong to

monocytic-macrophage system and function as phagocytic cells.

315. Intercostal nerve is a branch of ?

- a) Brachial plexus
- b) Dorsal rami of thoracic spinal nerves
- c) Ventral rami of thoracic spinal nerves
- d) Ventral rami of cervical spinal nerves

Correct Answer - C

Ans. is 'c' i.e., Ventral rami of thoracic spinal nerves

Ventral rami of upper 11th thoracic spinal nerves are known as intercostal nerves and ventral ramus of T12 is known as subcostal nerve.

Upper six intercostal nerves supply thoracic wall whereas lower five intercostal nerves and subcostal nerve supply thoracic and anterior abdominal walls and hence known as *thoracoabdominal nerves*.

Upper two intercostal nerves also supply the upper limb.

Thus only 3rd to 6th are called typical intercostal nerves.

316. Action of popliteus muscle ?

a) Medial rotation of femur

b) Lateral rotation of femur

c) Locking of knee

d) Extension of knee

Correct Answer - B

Ans. is 'b' i.e., Lateral rotation of femur

Popliteus

- Popliteus is a deep muscle of posterior compartment of leg.
- Features of popliteus are ?
Origin
 - Lateral surface of lateral condyle of femur, origin is intracapsular.
 - Outer margin of lateral meniscus of knee.**Insertion**
 - *Posterior surface of shaft of tibia above soleal line.***Nerve supply**
 - Tibial nerve**Action**
 - *Unlocks knee joint* by lateral rotation of femur on tibia prior flexion.
 - Accessory flexor of knee

317. Left gastric artery is a branch of ?

a) Hepatic artery

b) Splenic artery

c) Superior mesenteric artery

d) Coeliac trunk

Correct Answer - D

Ans. is 'd' i.e., Coeliac trunk

Arterial supply of stomach is as follows -

- *Along lesser curvature* : Left gastric artery (branch of coeliac trunk) and right gastric artery (branch of proper hepatic artery).
- *Along greater curvature* : Right gastroepiploic artery (branch of gastroduodenal artery) and left gastroepiploic artery (branch of splenic artery).
- *Fundus* 5-7 short gastric arteries (branches of splenic artery).
- Most consistently largest artery to stomach is left gastric artery.

318. Superior angle of scapula lies at which level ?

a) T₇

b) T₁₂

c) T₂

d) C₅

Correct Answer - C
Ans. is 'c' i.e., T₂

319. Short gastric artery is a branch of ?

a) Coeliac trunk

b) Splenic artery

c) Hepatic artery

d) Superior mesentric artery

Correct Answer - B

Ans. is 'b' i.e., Splenic artery

320. Primordial Germ cell of ovary are developed from ?

a) Ectoder

b) Mesoderm

c) Endoderm

d) Coelomic epithelium

Correct Answer - C
Ans. is 'c' i.e., Endoderm

321. Crystalline lens develops from ?

a) Mesoderm

b) Endoderm

c) Surface ectoderm

d) Neuroectoderm

Correct Answer - C

Ans. is 'c' i.e., Surface ectoderm

322. Direction of nasolacrimal duct is ?

a) Downwards, backwards and medially

b) Downwards, backwards and laterally

c) Downwards, forwards and medially

d) Downwards, forwards and laterally

Correct Answer - B

Ans. is 'b' i.e., Downwards, backwards and laterally

Nasolacrimal duct : It is a membranous passage which begins at the lower end of the lacrimal sac. It runs downwards, backwards and laterally and opens in the inferior meatus of the nose.

323. Bronchopulmonary segment is supplied by ?

a) Primary bronchus

b) Secondary bronchus

c) Tertiary bronchus

d) Principal bronchus

Correct Answer - C

Ans. is 'c' i.e., Tertiary bronchus

It is supplied independently by a segmental (tertiary) bronchus and a tertiary branch of the pulmonary artery.

324. Nerve supply of Teres major is ?

a) Suprascapular nerve

b) Axillary nerve

c) Upper subscapular

d) Lower subscapular nerve

Correct Answer - D

Ans. is 'd' i.e., Lower subscapular nerve

325. Not a content of Hunter's canal ?

a) Femoral artery

b) Femoral vein

c) Femoral nerve

d) Sphenous nerve

Correct Answer - C

Ans. is 'c' i.e., Femoral nerve

Contents of adductor canal are femoral artery, femoral vein, Saphenous nerve, nerve to vastus medialis, *descending genicular artery, deep lymph vessels, and two terminal divisions of obturator nerve.*

326.

All are true about 1st part of duodenum, except ?

a) 5 cm long

b) Is superior part

c) Develops from foregut

d) Supplied by superior mesenteric artery

Correct Answer - D

Ans. is 'd' i.e., Supplied by superior mesenteric artery

Duodenum

- Duodenum is 'C' shaped, shortest, widest and most fixed part of small intestine. It is 25 cm long. It is devoid of mesentery. *Most of the duodenum is retroperitoneal and fixed*, except at its two ends where it is suspended by folds of peritoneum, and is therefore mobile. Duodenum lies opposite L1, L2 and L3 vertebrae.
- Duodenum is C-shaped curve which encloses the head of pancreas and is subdivided into four parts :
 1. First part (Superior part) : It is 5 cm (2 inches) long. It begins at the pylorus and meet the second part at superior duodenal flexure. This part appears as duodenal cap on barium studies.
 2. Second part (Descending part) : It is about 7.5 cm (3 inches) long. It is vertical part which begins at superior duodenal flexure and meet the third part at inferior duodenal flexure. The interior of second part of duodenum shows following features :
 - i) *Major duodenal papilla* : It is present 8-10 cm distal to the pylorus. The hepatopancreatic ampulla or ampulla of Vater (joint part of bile duct and pancreatic duct) opens here.
 - ii) *Minor duodenal papilla* : It is present 6-8 cm distal to the pylorus. **Accessory pancreatic duct opens here.**

3. Third part (Horizontal part) : It is 10 cm (4 inches) long. It begins at inferior duodenal flexure and passes towards the left in front of IVC behind superior mesenteric vessels and root of mesentery to meet 4th part of duodenum.

- Fourth part : It is 2-5 cm (1 inches) long and runs upward immediately to the left of aorta. It ends at duodenojejunal flexure by joining the jejunum.

Arterial supply

- The part of duodenum before the opening of bile duct (major duodenal papilla) develops from foregut and therefore is supplied by *coeliac trunk* through superior pancreaticoduodenal artery, a branch of gastroduodenal artery, which in turn is a branch of common hepatic artery. Part of duodenum distal to opening of bile duct is developed from midgut and therefore is supplied by *superior mesenteric artery* through inferior pancreaticoduodenal artery. First part of duodenum receives additional supply from *right gastric artery*, *supraduodenal artery* (a branch of common hepatic artery), retroduodenal branch of gastroduodenal artery and right gastropiploic artery.

327. Internal pudendal artery is a branch of ?

a) Anterior division of internal iliac

b) Posterior division of internal iliac

c) Anterior division of external iliac

d) Posterior division of external iliac

Correct Answer - A

Ans. is 'a' i.e., Anterior division of internal iliac

Branches of anterior division of internal iliac artery are : (i) Superior vesical, (ii) Middle rectal, (iii) Inferior vesical (in males), (iv) *Internal pudendal*, (v) Vaginal (in females), (vi) *Uterine* (in females), (vii) *Obturator*, and (viii) *Inferior gluteal*.

Branches of posterior division are : (i) *Iliolumbar*, (ii) Lateral sacral, and (iii) Superior gluteal.

328. Which muscle of extensor Compartment flexes the elbow ?

a) ECRL

b) ECU

c) Anconeus

d) Brachioradialis

Correct Answer - D
Ans. is `d' i.e., Brachioradialis

329. True about trapezius are all except ?

- a) Elevates the scapula
- b) Originates for C7
- c) Supplied by cranial part of accessory nerve
- d) Causes over-head abduction

Correct Answer - C

Ans. is 'c' i.e., Supplied by cranial part of accessory nerve

The trapezius muscle is a postural and active **movement** muscle, used to tilt and turn the head and neck, shrug, steady the shoulders, and twist the arms.

The trapezius elevates, depresses, rotates, and retracts the scapula, or shoulder blade.

Innervation of the trapezius is derived from the spinal accessory nerve.

330. Which of the following is a derivative of ventral mesogastrium ?

a) Greater omentum

b) Gastrosplenic ligament

c) Linorenal ligament

d) Lesser omentum

Correct Answer - D
Ans. is 'd' i.e., Lesser omentum

331. Which flexor muscle is attached to hook of hamate?

a) Flexor pollicis brevis

b) Flexor pollicis longus

c) Flexor digiti minimi

d) Flexor carpi ulnaris

Correct Answer - C

Ans. is 'c' i.e., Flexor digiti minimi

332. Nerve supply to musculature of urinary bladder is ?

a) Sympathetic

b) Parasympathetic

c) Both

d) None

Correct Answer - C

Ans. is 'c' i.e., Both

Parasympathetic supply is motor to detrusor muscle and inhibitory to sphincter vesicae. Sympathetic supply is motor to sphincter vesicae and inhibitory to detrusor muscle.

Nerve supply of bladder

Bladder is supplied by both sympathetic and parasympathetic fibers.

Parasympathetic : Preganglionic fibers arise from S₂ to S₄ cord segments, pass via pelvic splanchnic nerves. After relay in ganglion cells in pelvic plexus (inferior hypogastric plexus) and in bladder wall, postganglionic fibers supply detrusor muscle. Contraction of detrusor muscle is mediated by cholinergic muscarinic receptors (M₃).

Preganglionic parasympathetic neurons at S₂, and S₄ cord segments innervating bladder form sacral micturition center.

Sympathetic : Preganglionic fibers arise from lateral horn cells of T₁-L₂ cord segments and pass via lower lumbar splanchnic nerves, superior hypogastric plexus (presacral nerve of Latarjet) to reach inferior hypogastric (pelvic) plexus. After relay in pelvic ganglia, postganglionic sympathetic fibers (i) stimulate sphincter vesicae (internal urethral sphincter) via α , adrenoceptors and (ii) cause

relaxation of detrusor muscle via 13_2 adrenoceptors. It can also inhibit presynaptically the parasympathetic ganglia via α_1 adrenoceptors

Visceral afferents : (1) pain fibers from bladder pass through both parasympathetic and sympathetic pathway and enter T_{11} - L_2 and S_2 - S_4 cord segments, hence referred pain is felt in lower part of anterior abdominal wall (hypogastrium), upper part of front of thigh, scrotum or labium majus, penis or clitoris, and perineum. Centrally, spinothalamic pathway conducts pain impulses from bladder.

Stretch afferents : arising from stretch receptors in the bladder wall pass via pelvic splanchnic nerves, enter S_2 , S_3 and S_4 cord segments and establish reflex connections with sacral micturition center, which innervates detrusor.

So afferent and efferent limb of this micturition reflex is formed by pelvic splanchnic nerves.

Sacral micturition center and the micturition reflex are controlled by facilitatory and inhibitory centers located in pons and paracentral lobule of frontal lobe of cerebrum.

333. Major protein of bone is ?

a) Osteocalcin

b) Osteopontin

c) Collagen type- 1

d) Collagen type- 4

Correct Answer - C

Ans. is 'c' i.e., Collagen type-1

Bone is a specialized *connective tissue*.

Bone components are :?

1) Inorganic elements (65%)

2) Organic matrix (35%)

1) Inorganic elements

- It is the mineral phase, principally composed of calcium and phosphate, mostly in the form of hydroxyapatite $[Ca_{10}(PO_4)_6(OH)_2]$.

2) Organic matrix

- Organic matrix consists of cells of bones and protein of matrix. This unmineralized matrix is called osteoid, i.e. *unmineralized bone is known as osteoid*. Osteoid with mineral (i.e. mineralized osteoid) is complete bone.

A) *Protein of matrix*

It is mainly formed by *type I collagen* and a family of noncollagenous proteins like osteocalcin and osteonectin that are derived mainly from osteoblasts.

B) *Cells of matrix*

The cells of bone are :-

i) *Osteoblasts*

ii) *Osteoclasts*

iii) Osteocytes

334. Function of flocculonodular lobe of cerebellum ?

a) Postural balance

b) Smoothing of movement

c) Planning of movement

d) All of the above

Correct Answer - A
Ans. is 'a' i.e., Postural balance

335. Hormone involved in regulation of BP ?

a) Serotonin

b) Angiotensin- II

c) Dopamine

d) Prostaglandin

Correct Answer - B

Ans. is 'b' i.e., Angiotensin- II

336. Macula densa is derived from ?

a) Afferent arteriole

b) Efferent arteriole

c) DCT

d) PCT

Correct Answer - C

Ans. is 'c' i.e., DCT

- The ascending limb of the loop of Henle proceeds towards its own glomerulus, so that a portion of the distal convoluted tubule comes to lie very close to the afferent and efferent arterioles.
- The juxtaglomerular apparatus is located at the angle of the *afferent and efferent arterioles*, where it comes in contact with the distal tubules.
- It comprises the macula densa, juxtaglomerular (JG cells), and the lacis cells.
- The part of the distal tubule which comes in contact with the afferent arteriole is made of a specialized epithelium called the macula densa.
- The juxtaglomerular (granular) cells are modified smooth muscle cells in the scaly media of the terminal part of the afferent arteriole.
- They contain large granules and secrete renin.
- JG cells are densely innervated by sympathetic nerve terminals and they release renin in response to sympathetic discharge.
- The lacis cells (extraglomerular mesangial cells) that are located in the angular space between the junction of afferent and efferent arterioles.
- The lacis cells also contain some renin.

337. Oxygen comes from alveoli to blood by ?

a) Diffusion

b) Receptor mediated

c) Active transport

d) Osmosis

Correct Answer - A

Ans. is 'a' i.e., Diffusion

Oxygen is transferred from the alveoli to the pulmonary capillaries by the process of diffusion. The diffusion occurs across the respiratory membrane.

As oxygen diffuses into the blood, it *combines with hemoglobin*. However, the oxygen, in combination with hemoglobin, does not contribute to the PO_2 of blood. Therefore the alveolar - capillary gradient of PO_2 is maintained much longer than it would be if hemoglobin were not present. The sequence may be visualized as follows:-

i) Oxygen diffuses from the alveoli into the plasma due to the PO_2 gradient.

ii) To start with, the PO_2 in the RBC fluids is the same as in the plasma. As soon as diffusion from the alveoli to plasma raises the PO_2 of plasma above that of the RBC fluids, oxygen diffuses from the plasma into the RBC.

iii) As soon as oxygen enters the RBC, it combines with hemoglobin, which mops up oxygen but does not let PO_2 rise. The process continues till hemoglobin cannot pick up any more oxygen.

iv) Then the PO_2 in the RBC fluids rises to equal that in the plasma and diffusion from the plasma to RBC stops.

v) After that the PO_2 in the plasma also rises to equal that in the alveoli, and consequently diffusion from the alveoli to the plasma stops.

Thus, the presence of hemoglobin makes an enormous difference to the amount of oxygen transferred. By mopping up oxygen without letting the PO_2 rise, it lets the diffusion of oxygen continue much longer. *While the PO_2 gradient determines the direction of diffusion of oxygen, it is actually hemoglobin that lays the trap for carrying large amounts of oxygen in the blood.*

338. Temporal lobectomy in monkey leads to ?

a) Hypersensitivity

b) Aggressive behavior

c) Hypersexuality

d) None

Correct Answer - C

**Ans. is 'c' i.e., Hypersexuality
Kluver-Bucy syndrome**

Kluver-Bucy syndrome is a neuro-behavioural syndrome associated with bilateral lesions in the anterior temporal horn or amygdala.

Heinrich Kluver and Paul Bucy first described the syndrome in 1937 after experimental work where they removed rhesus monkey's temporal lobes. They found that the monkeys developed.

1) *Visual agnosia* : they could see, but were unable to recognise familiar objects or their use.

2) *Oral tendencies* : they would examine their surroundings with their mouths instead of their eyes.

3) *Hypermetamorphosis* : a desire to explore everything.

4) *Emotional changes* : emotion was dulled and facial movements and vocalisations were far less expressive. They lost fear where it would normally occur. Even after being attacked by a snake, they would casually approach it again. This was called "placidity".

5) *Hypersexuality* : a dramatic increase in overt sexual behaviour, including masturbation, and homosexual and heterosexual acts.

They may even attempt copulation with inanimate objects.

The syndrome in humans is due to bilateral destruction of the amygdaloid body and inferior temporal cortex, most commonly due

to herpes simplex encephalitis (HSE). It shares visual agnosia and loss of normal fear and anger responses in common with the monkey model but one also seen loss of memory with dementia, distractibility and seizures. The hypersexuality tends to be less overt than in the monkeys but may be public and unacceptable.

339. Following is true about spinal injuries except ?

a) Forms 6% of all trauma cases

b) Neurodeficit is present in 50% of all the cases

c) Traumatic injuries most commonly affect the cervical spine

d) Cervical spine is more prone to fracture than dislocation

Correct Answer - D

Ans. is 'd' i.e., Cervical spine is more prone to fracture than dislocation

Spinal injuries:

- Spinal injury occurs in about 6% of all trauma cases.
- More than 50% of patients with spinal column injury have neurological deficit.
- *Motor vehicular accidents and fall from height are the two most common modes of spine injuries :-*
 - Fall from height :- Most common cause in developing countries.*
 - Road traffic accident :- Most common cause in developed countries.*
- *Traumatic spine injuries most commonly affect cervical spine (50-60%) followed by dorsolumbar junction.*
- The direction and size of the articular facets forming the facet joints is different in different parts of the spine. o In cervical spine, they are short and more horizontally placed; therefore, cervical spine is more prone for dislocation without associated fracture.
- In lower spine they becomes more stouter and more vertical, maximum in lumbar spine. Therefore, pure dislocation without fracture does not occur in lumbar region.

340. Which of the following nerve nucleus underlies the facial colliculus?

a) Abducent

b) Vestibulocochlear

c) Facial

d) Trigeminal

Correct Answer - A

Ans. a. Abducent

'Facial colliculus is situated in the pons, It overlies the abducent nucleus. The facial nerve originates from its nucleus and goes around the abducent nerve. This is called ss neurobotaxis- Gray's 40/ep240

341. All of the following are true about cavernous sinus thrombosis except?

a) Most commonly spreads through ethmoid sinus

b) Loss of sensation around orbit

c) Loss of jaw jerk

d) Infection can spread to cavernous sinus from danger area of face via inferior ophthalmic vein

Correct Answer - C

Ans. c. Loss of jaw jerk

Any spreading infection involving the upper nasal cavities, paranasal sinuses, cheek (especially near the medial canthus), upper lip, anterior nares or even an upper incisor or canine tooth, may very rarely lead to septic thrombosis of the cavernous sinuses; infected thrombi pass from the facial vein or pterygoid venous complex into the sinus via either ophthalmic veins or emissary veins that enter the cranial cavity through the foramen ovale. This is a critical medical emergency with a high risk of

Cavernous Sinus Thrombosis

- Usually results from infection of ethmoid and sphenoid sinusesQ

Route of Spread

Ethmoid sinus (MC) via ophthalmic veins°	Orbit by ophthalmic veins°
Sphenoid sinus by direct spread°	Upper lid via angular vein and ophthalmic veins°
Frontal sinus via	—

supraorbital and ophthalmic veins° Ear by petrosal venous sinuses

Clinical Features:

- Onset is abrupt with fever, chills and rigor
- Involvement of 3rd, 4th, 5th and 6th cranial nerve
- Chemosis of conjunctiva^Q
- Proptosis of eye with limited movements^Q
- Pupils are dilated and fixed^Q (due to involvement of sympathetic plexus around carotid artery)
- Decreased vision^Q(due to optic nerve damage)
- Decreased sensation in distribution of 5th nerve (ophthalmic division) and engorgement of retinal vessels^Q

Treatment:

- Antibiotics in high doses for 4-6 weeks and drainage of involved sinuses^Q

342. Valve of Hasner ?

a) Opening of nasolacrimal duct

b) Sphenoidal sinus opening

c) Frontal sinus opening

d) Ethmoidal sinus opening

Correct Answer - A

Ans. is 'a' i.e., Opening of nasolacrimal duct

Lateral wall of nose

- It has 3 bony projections called as turbinates or conchae. From below upwards they are inferior, middle and superior turbinates. *The inferior turbinate is a separate bone, while rest of the turbinates are a part of ethmoidal bone.* Below and lateral to each turbinate is the corresponding meatus. Inferior turbinate is largest one.
 1. Inferior meatus
 - It is the largest meatus. Its highest point is the junction of anterior and middle 1 /3rd. Nasolacrimal duct opens in the inferior meatus, just anterior to its highest point (it is closed by a mucosal flap called Hasner's valve).
 2. Middle meatus
 - It lies below the middle turbinate (middle concha), i.e. between middle turbinate and inferior turbinate. The important structures in middle meatus are :-
 - Hiatus semilunaris
 - *Ethmoidal infundibulum :- Frontal sinus, maxillary sinus and the anterior ethmoidal sinuses drain into it.*
 - Anterior /Posterior fontanelle :- Accessory ostia are found mostly in the posterior fontanelle.
 - Uncinate process :- It partly covers the opening of maxillary sinus.

- Bulla ethmoidalis :- Middle ethmoidal sinuses open on or above it.
- Atrium is a shallow depression in front of the middle turbinate. Agger nasi is an elevation just anterior to the attachment of middle turbinate.
 - 3. Superior meatus
- It lies below the superior turbinate and *posterior ethmoidal sinuses open into it.*
 - 4. Spheno-ethmoidal recess
- It lies above the superior turbinate and *receives the opening of sphenoid sinus.*

343. Root value of thoracodorsal nerve ?

a) C₅,C₆,C₇

b) C₈,T₁

c) C₆,C₇,C₈

d) T_i T₂

Correct Answer - A

Ans. is 'c' i.e., C₆C₇C₈

Branches of brachial plexus

- Branches of brachial plexus arises from different anatomical segments : -
 1. Branches of the roots
- Nerve to serratus anterior (long thoracic nerve) (C₅, C₆, C₇).
- Nerve to rhomboideus (dorsal scapular nerve) (C₅).
- 2. Branches of the trunks
- These arise only from the upper trunk which gives two branches. I.
 - Suprascapular nerve (C₅, C₆)
- Nerve to subclavius (C₅, C₆)
- 3. Branches of the cords
 1. *Branches of lateral cord*
- Lateral pectoral (C₅-C₇)
- Musculocutaneous (C₅-C₇)
- Lateral root of median (C₅-C₇)
- 2. *Branches of medial cord*
- Medial pectoral (C₈, T₁)
- Medial cutaneous nerve of arm (C₈, T₁)
- Medial cutaneous nerve of forearm (C₈, T₁).

- Ulnar (C7, C8, T₁). C7 fibres reach by a communicating branch from lateral root of median nerve.
- Medial root of median (C₈, T₁).
 - 3. Branches of posterior cord
- Upper subscapular (C₅, C6)
- Nerve to latissimus dorsi (thoracodorsal) (C6, C7, C₈)
- Lower subscapular (C₅, C6)
- Axillary (circumflex) (C₅, C6)
- Radial (C₅-C₈, T₁)

344. Superior cerebellar peduncle contains mainly which tract ?

a) Tectocerebellar

b) Olivocerebellar

c) Vestibulo cerebellar

d) Reticulo cerebellar

Correct Answer - A

Ans. is 'a' i.e., Tectocerebellar

Superior cerebellar peduncle

- This is the major output of the brain and connects to the midbrain, via the cerebellothalamic tract (to the thalamus), and the cerebellorubral tract (to the red nucleus). It receives afferents from the locus coeruleus, and ventral spinocerebellar tract.

Middle cerebellar peduncle

- This is the largest peduncle and connects the cerebellum to the pons. It connects the contralateral pontine nucleus to the cerebellar cortex and also carries the input from the contralateral cerebral cortex. It is composed of three fasciculi including the superior, inferior and deep.

Inferior cerebellar peduncle

- This connects the spinal cord and medulla to the cerebellum. The posterior spinocerebellar tract receives proprioceptive information from the body. The cuneocerebellar tract receives proprioceptive input from the upper limb and neck. The trigeminocerebellar tract sends proprioceptive input from the face. The juxtarestiform is an efferent system here.

345.

Lymphatic drainage of anterior part of nose is to?

a) Submandibular LN

b) Parotid

c) Pretracheal LN

d) Retropharyngeal LN

Correct Answer - A

Ans. is 'a' i.e., Submandibular LN

- Anterior half of nasal cavity (including anterior part of nasal septum) drains into submandibular nodes.
- Vessels from the posterior two thirds of the nasal cavity and from the ethmoid sinuses drain partly to the retropharyngeal nodes and partly to the superior deep cervical nodes.

346. Length of LES is ?

a) 1-2 cm

b) 3-4 cm

c) 1-2 mm

d) 3-4 mm

Correct Answer - B

Ans. is 'b' i.e., 3-4 cm

- The **lower esophageal sphincter** (LES) is a bundle of muscles at the low end of the **esophagus**, where it meets the stomach.
- When the LES is closed, it prevents acid and stomach contents from traveling backwards from the stomach.
- The LES muscles are not under voluntary control.
- Lower esophageal splincter is at diaphragmatic constriction.
- Normal abdominal LES length (3.1cm)
- The basal **pressure** of the LES is 10–45 mmHg.
-

347. Posterior relation of portal vein -

a) 1st part of duodenum

b) Hepatic artery

c) Bile duct

d) IVC

Correct Answer - D

Ans. is 'd' i.e., IVC

- The portal vein is about 8 cm long. It is formed by the *union of the superior mesenteric veins and the splenic vein behind the neck of the pancreas* at the level of the second lumbar vertebra. The inferior mesenteric vein drains into the inferior mesenteric vein.

Important facts about portal vein

- 8 cm long
- The blood flow is slow
- *Stream line flow* :- Blood in superior mesenteric vein drains, into right lobe of liver. Blood in splenic and inferior mesenteric vein drains into left lobe.
- Relations
 - Infraduodenal part
 - .. Anterior :- Neck of pancreas
 - ?. Posterior :- IVC
 - Retroduodenal part
 - .. Anterior :- Ppart of duodenum, bile duct, gastroduodenal artery
 - ?. Posterior :- IVC
 - Supraduodenal part
 - .. Anterior :- Hepatic artery, bile duct.
 - ?. Posterior :- IVC, separated by epiploic foramen
- Development of Portal vein :

1. Infra-duodenal part - part of left vitelline vein distal to the dorsal anastomosis
 2. Retro-duodenal part - dorsal anastomosis between two vitelline veins
 3. Supra-duodenal part - cranial part of right vitelline vein
- The portal vein receives the following veins :
 1. Splenic vein
 2. Superior mesenteric vein
 3. Left gastric
 4. Right gastric
 5. Superior pancreatico-duodenal
 - Cystic
 - Paraumbilical veins

348. Structure passing deep to medial malleolus is ?

a) Post tibial artery

b) Long saphenous vein

c) Tibialis ant. tendon

d) Peroneus tertius

Correct Answer - A

Ans. is 'a' i.e., Post tibial artery

- Posterior tibial artery terminates behind the medial malleolus by dividing into medial and lateral plantar arteries.

349. All are true regarding axillary lymph nodes except?

a) Posterior group lies along subscapular vessels

b) Lateral group lies along lateral thoracic vessels

c) Apical group lies along axillary vessels

d) Apical group is terminal lymph nodes

Correct Answer - B

Ans. is 'b' i.e., Lateral group lies along lateral thoracic vessels

Axillary lymph nodes

- The axillary lymph nodes are divided into 5 groups :?
 1. Anterior (pectoral) group :- Lie along lateral thoracic vessels, i.e. along the lateral border of pectoralis minor. They receive lymph from upper half of the anterior wall of trunk and from major part of breast.
 2. Posterior (scapular) group :- Lie along the Subscapular vessels. They receive lymph from the upper half of the posterior wall of trunk and axillary tail.
 3. Lateral group :- Lie along the upper part of the humerus, medial to the axillary vein. They receive lymph from upper limb.
 4. Central group :- Lie in the fat of the upper axilla. They receive lymph from the preceding groups and drain into apical group. The intercostobrachial nerve is closely related to them.
 5. Apical (infraclavicular) group :- Lie deep to the clavipectoral fascia along the axillary vessels. They receive lymph from central group, upper part of breast and the thumb and its web. These are called terminal group of lymph nodes, as they receive lymphatics from other nodes of breast.

350. Not true about right bronchus

a) Shorter

b) Wider

c) More horizontal

d) In the line of trachea

Correct Answer - C

Ans. is 'c' i.e., More horizontal

- Trachea bifurcates at Carina (at lower border of T4 vertebra at T₄-T₅ disc space) into *right and left principal (primary) bronchi*.
- Right principal bronchus is wider, shorter (2.5 cm long), and more vertical in the line of trachea (25° with median plane).
- Therefore a foreign body is most likely to lodge in the right bronchus.
- Right bronchus divides into epiarterial and hyparterial bronchi, passing respectively above and below the pulmonary artery, before entering the hilum.
- Left principal bronchus is narrower, longer (5 cm long) and more horizontal (45° with median plane).
- Left bronchus crosses in front of the esophagus producing a slight constriction.
- Inside the lung it divides into 2 lobar bronchi: upper and lower.

351. In case of aberrant obturator artery, it arises most commonly from ?

a) Common iliac artery

b) Femoral artery

c) Profunda femoris artery

d) Inferior epigastric artery

Correct Answer - D

Ans. is 'd' i.e., Inferior epigastric artery

Accessory obturator artery is the pubic branch of the inferior epigastric artery?

- The normal obturator artery is a branch of the internal iliac. It gives a pubic branch which anastomoses with the pubic branch of the inferior epigastric artery.
- Occasionally, this anastomosis is large and the obturator artery then appears to be a branch of the inferior epigastric.
- Usually, the abnormal (accessory) artery passes lateral to the femoral canal in contact with the femoral vein and is safe in an operation to enlarge the femoral ring.
- Sometimes, however, the abnormal obturator artery may lie along the medial margin of the femoral ring, i.e. along the free margin of the lacunar ligament. The femoral ring is enlarged by cutting the lacunar ligament.
- So, in this case the artery is likely to be cut.

352. All are true about esophagus except ?

a) Lined by stratified squamous epithelium

b) Mucosa is thick

c) Middle third contains both skeletal and smooth muscles

d) Lower third contains only skeletal muscle

Correct Answer - D

Ans. is 'd' i.e., Lower third contains only skeletal muscle

Important features of esophagus

- Epithelium is stratified squamous non-keratinized epithelium.
- Muscularis mucosa contains only longitudinal layer and no circular layer.
- Mucosa is the toughest and strongest layer.
- Serosa is absent.
- Muscularis externa is made up of skeletal muscle fibers only in the upper third, smooth muscles only in the lower third and both types of muscle fibers in middle third. At upper end the longitudinal coat splits into two bundles and the triangular interval between them is called Laimer's tringle which is filled with circular muscle fibers.

353. Boundaries of anatomical snuff box are all except

a) APL

b) EPL

c) EPB

d) ECU

Correct Answer - D

Ans. is 'd' i.e., ECU

Anatomical Snuffbox

- Triangular depression on the dorsal and radial aspect of the hand become visible when thumb is fully extended. Boundaries
- Medial/Posterior → Tendon of the *extensor pollicis longus*.
- Lateral/Anterior → Tendon of the *extensor pollicis brevis* and *abductor pollicis longus*.
- Roof Skin and → fascia with beginning of cephalic vein and crossed by superficial branch of the radial nerve.
- Floor → Styloid process of radius, trapezium, scaphoid and base of 1st metacarpal.
- Contents → The radial artery.

354. Nerve root of pudendal nerve is ?

a) S₁S₂S₃,

b) S₂S₃S₄,

c) S₃-S₄,

d) S₂-S₃

Correct Answer - B

Ans. is 'b' i.e., S₂S₃S₄

Nerve	Root value
Sciatic nerve	L 4, 5 S 1,2,3 L
Tibial nerve	4, 5 S 1,2,3
Common peroneal nerve	L4,5 S 1,2
Superior gluteal nerve	L 4,5 S 1
Inferior gluteal nerve	L 5 S 1,2
Nerve to quadratus femoris	L 4,5 S 1
Nerve to obturator internus	L 5 S 1,2
Superior gemellus	L 4,5 S 1
Inferior gemellus	L 4,5 S 1,2 S
Posterior cutaneous nerve of thigh	L2,3
Pudendal nerve	S2,3,4
Perforating cutaneous nerve	S2,3

355. Hyoid lies at the level of ?

a) C₃

b) C₄

c) C₇

d) T₂

Correct Answer - A

Ans. is 'a' i.e., C₃

Surface anatomy of larynx are :

- C₂, Level of body of hyoid and its greater cornu.
- C₃ -C₄, Junction Level of upper border of thyroid cartilage and bifurcation of common carotid artery. C₄- C₅, Junction Level of thyroid cartilage.
- C₆ Level of cricoid cartilage.

356. Which of the following nerve carries fibres from all the roots of brachial plexus ?

a) Axillary

b) Ulnar

c) Median

d) Musculocutaneous

Correct Answer - C

Ans. is 'c' i.e., Median

Only two nerves carry fibres from all the roots of brachial plexus, i.e. C₅ to T₁, :?

1. Median nerve (C₅- T₁)
- Lateral root (C₅ - C₇)
 - Medial root (C₈ T₁)
2. Radial nerve (C₅ - T₁)

357. Branches of brachial artery are all except ?

a) Profunda brachii

b) Superior ulnar collateral

c) Inferior ulnar collateral

d) Radial collateral

Correct Answer - D

Ans. is 'd' i.e., Radial collateral

- Radial collateral is a branch of profunda brachii artery, which in turn is a branch of brachial artery (Radial collateral artery is not a direct branch of brachial artery).

Brachial artery

- It begins as a continuation of axillary artery at level of lower border of teres major muscles. It terminates in the cubital fossa, opposite the level of neck of radius by dividing into radial and ulnar arteries. It gives following branches?
 1. Profunda brachii :- Accompanies radial nerve in the spiral groove and gives following branches?
 - .. Deltoid branch (ascending branch) :- It anastomoses with the descending branch of posterior circumflex humeral artery.
 2. Nutrient artery to humerus:
 3. Muscular branches
 4. Posterior descending (middle collateral) :- It anastomoses with interosseous recurrent branch of ulnar artery.
 5. Anterior descending (radial collateral) :It anastomoses with radial recurrent branch of radial artery in front of lateral epicondyle.
 2. Superior ulnar collateral artery :-Anastomoses with posterior ulnar recurrent branch of ulnar artery behind medial epicondyle.

3. Muscular branches

4. Inferior ulnar collateral (Supratrochlear artery) :- Anastomoses with anterior ulnar recurrent branch of ulnar artery in front of medial epicondyle.

358. Internal spermatic fascia is derived from ?

a) External oblique muscle

b) Internal oblique muscle

c) Fascia transversalis

d) Colle's fascia

Correct Answer - C

Ans. is 'c' i.e., Fascia transversalis

Layers of the scrotum

- The scrotum is made up of the following layers from outside inwards.
 1. Skin, continuation of abdominal skin.
 2. Dartos muscle which replaces the superficial fascia. The dartos muscle is prolonged into a median vertical septum between the two halves of the scrotum.
 3. The external spermatic fascia from external oblique muscle.
 4. The cremasteric muscle and fascia from internal oblique muscle.
 5. The internal spermatic fascia from fascia transversalis

359. Flexion of metacarpophalangeal joint is produced by?

a) Lumbricals

b) Dorsal interossei

c) Palmar interossei

d) All of the above

Correct Answer - D

Ans. is 'd' i.e., All of the above

Metacarpophalangeal joints

- o These are ellipsoid joints between head of metacarpals and base of proximal phalanx. Movement at MCP joints are flexion, extension, abduction and adduction.

Movement Muscles producing movements

Flexion Main muscles :- The lumbricals and the interossei.

Supportive :- Flexor digitorum profundus and superficialis.

Extension Main muscles :- Extensor digitorum.

Supportive muscles :-

Extensor indicis (for index finger), Extensor digiti minimi (for little finger)

Adduction Palmar interossei

Abduction Dorsal interossei

Important fact

- MCP joint is functionally an ellipsoid joint, but it is condylar joint structurally.

360. Axillary sheath is derived from?

a) Prevertebral fascia

b) Pretracheal fascid

c) Investing layer of deep cervical fascia

d) Deep fascia of throacic wall

Correct Answer - A

Ans. is 'a' i.e., Prevertebral fascia

The deep cervical fascia (fascia colli) has the following 6 layers:

- Investing layer
- Lies deep to the platysma
- Forms a pulley to hold tendons of digastrics and omohyoid
- Splits to enclose the parotid and submandibular glands; the suprasternal and supraclavicular spaces; and the sternocleidomastoid and trapezius
- Pretracheal layer
- Encloses larynx, trachea, esophagus and infrahyoid strap muscles
- Forms false capsule of the thyroid and the suspensory ligament of Berry
- Prevertebral fascia
- Forms axillary sheath around subclavian artery and brachial plexus
- Subclavian vein lies outside this sheath
- Carotid sheath
- Encloses the internal carotid artery, internal jugular vein and vagus nerve.
- Buccopharyngeal fascia
- Lies on the superficial aspect of the buccinators muscle and covers the superior constrictor muscle externally
- Pharyngobasilar fascia

- Lies deep to the pharyngeal muscles.

361. which level the somites initially form ?

a) Thoracic level

b) Cervical level

c) Lumbar level

d) Sacral level

Correct Answer - B

Ans. is 'b' i.e., Cervical level

- The first pair of somites develop a short distance posterior to the cranial end of the notochord, and the rest of the somites from caudally.
- "By the 20" day, the first pair of somites have formed in neck region." Textbook of embryology
- Paraxial mesoderm differentiates into somites. By the end of 20th day, the first pair of somites have formed in neck region. After this, about 3 pairs of somites are formed per day and by the end of 5" week about 42-44 somite pairs are formed (4-occipital, 8-cervical, 12-thoracic, 5-lumbar, 5-sacral and 8-10 coccygeal). Somites are further differentiated into :-
- Dermatomyotome :- Give rise to skeletal muscles and dermis.
- Sclerotomes :- Give rise to vertebral column.

362. Meckel's diverticulum is a remnant of ?

a) Stenson's duct

b) Wolffian duct

c) Mullerian duct

d) Vitellointestinal duct

Correct Answer - D

Ans. is 'd' i.e., Vitellointestinal duct

Meckel's diverticulum

- Meckel's diverticulum is the persistent proximal part of the vitellointestinal duct which normally disappears during intrauterine life.
- It follows '*rule of 2*' :- present in 2% subjects, 2 inches (5 cm) long and is situated 2 feet (60 cm) proximal to ileocecal valve.
- It is attached to antimesenteric border of ileum.
- Its calibre is equal to that of the ileum.
- Its apex may be free or attached to umbilicus or mesentery by a fibrous band. o Vitellointestinal duct possesses all three coats of intestinal wall.

363. Cephalic vein drains into ?

a) Brachial vein

b) Subclavian vein

c) Axillary vein

d) IVC

Correct Answer - C

Ans. is `c' i.e., Axillary vein

Veins of upper limb

- Cephalic vein is the paraxial vein of upper limb (like great saphenous vein of lower limb). It begins from the lateral end of dorsal venous arch. It is accompanied by lateral cutaneous nerve of forearm and terminal part of radial nerve.
- Basilic vein is the postaxial vein of upper limb (like short saphenous vein of lower limb). It begins from the medial end of dorsal venous arch. It is accompanied by posterior branch of medial cutaneous nerve of forearm and terminal part of dorsal branch of ulnar nerve.
- Basilic vein continues as axillary vein. Cephalic vein drains into axillary vein by : (i) Draining into basilic vein through median cubital vein (greater proportion), and (ii) Directly draining into axillary vein.

364. Purkinje cells of cerebellum are connected to ?

a) Basket cells

b) Stellate cells

c) Deep cerebellar nuclei

d) All of the above

Correct Answer - D

Ans. is 'd' i.e., All of the above

- The two main inputs to the cerebellar cortex are climbing fibers and mossy fibers, which are excitatory.
- The climbing fibers come from a single source, the inferior olivary nuclei and directly projects to the primary dendrites of a purkinje cell.

365. Base of the heart is formed by ?

a) Right atrium

b) Right ventricle

c) Left atrium

d) Left ventricle

Correct Answer - A:C

Ans. is `c > a' i.e., Left atrium > Right atrium

- Base (posterior surface) is formed mainly by left atrium and partly by right atrium. It is separated from T₅ to T₈ vertebrae by pericardium
- The **apex** (the most inferior, anterior, and lateral part as the **heart** lies in situ) is located on the midclavicular line, in the fifth intercostal space. It is **formed** by the left ventricle.
- Anterior (sternocostal) surface is formed mostly by right ventricle (major) and right auricle and partly by left ventricle and left auricle.

366. Upper two posterior intercostal arteries arise from ?

a) Aorta

b) Superior intercostal artery

c) Internal mammary artery

d) Bronchial artery

Correct Answer - B

Ans. B) Superior intercostal artery

- The 1st and 2nd **posterior intercostal arteries arise** from the supreme **intercostal artery**, a branch of the costocervical trunk of the subclavian **artery**.
- The lower nine **arteries** are the aortic**intercostals**, so called because they **arise** from the back of the thoracic aorta.

367. Extent of esophagus is ?

a) C₃ - C₆

b) C₆ - T₁₀

c) T₁₀ - T₁₂

d) None

Correct Answer - B

Ans. is 'b' i.e., C6-T10 Organ/Structure Larynx

368. Adductor pollicis is supplied by

a) Superficial branch of ulnar nerve

b) Deep branch of ulnar nerve

c) Superficial branch of median nerve

d) Deep branch of median nerve

Correct Answer - B

Ans. is 'b' i.e., Deep branch of ulnar nerve

369. Posterior relation of neck of pancreas ?

a) IVC

b) Origin of portal vein

c) Aorta

d) Common bile duct

Correct Answer - B

Ans. is 'b' i.e., Origin of portal vein

370.

Anterosuperior sternal part of heart is made up of ?

a) Right atrium and auricle

b) Left atrium.

c) Left ventricle

d) Right ventricle

Correct Answer - D
Ans. is 'd' i.e., Right ventricle

371. Typical feature of thoracic vertebrae ?

a) Heart shaped

b) Large body

c) Triangular vertebral foramen

d) None

Correct Answer - A

Ans. is 'a' i.e., Heart shaped

Thoracic vertebrae

- There are 12 thoracic vertebrae. *T2-T9 are typical thoracic vertebrae and T1, T10, T11, T12 are atypical thoracic vertebrae.*
 - Characteristic features of typical thoracic vertebra : -
 - Body is medium sized and heart shaped.
 - Spinous process is long and inclined downward.
 - Vertebral foramen is small and circular.
 - Transverse process possess costal facets for rib articulation (last two vertebrae lack these facets).
 - Costal facets are also present on the sides of body for articulation of heads of ribs.
 - Superior articular facet is directed backwards and laterally, and inferior articular facet faces forward and medially.
 - Articular processes are vertically placed and interlocked; So dislocation can only occur if they are fractured.
- SHAPE:
- The thoracic curve, concave forward, begins at the middle of the second and ends at the middle of the twelfth thoracic vertebra. Its most prominent point behind corresponds to the spinous process of the seventh thoracic vertebra. This curve is known as a kyphotic curve.

- The thoracic and sacral kyphotic curves are termed primary curves, because they are present in the fetus. The cervical and lumbar curves are *compensatory* or *secondary*, and are developed after birth

372. Median umbilical ligament is derived from ?

a) Proximal part of umbilical artery

b) Distal part of umbilical artery

c) Urachus

d) Umbilical vein

Correct Answer - C

Ans. is 'c' i.e., Urachus

Ligament

Median umbilical ligament

Ligamentum teres

Superior vesical ligament

Medial (not median) umbilical
ligament

Derived from

Remnant of urachus

Umbilical vein

Proximal part of umbilical
artery

Distal part of umbilical artery

373. False about Klumpke's paralysis?

a) Involves lower trunk of brachial plexus

b) Due to undue abduction of shoulder

c) Can cause Horner's syndrome

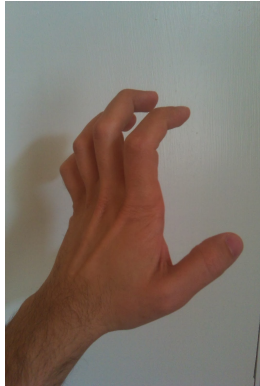d) Biceps brachii is paralysed

Correct Answer - D

In Klumpke's paralysis, injury to lower trunk of brachial plexus due to undue abduction of shoulder.

It can cause Horner's syndrome,
Biceps is not paralysed.

374. The following hand deformity is seen in?



a) Ulnar nerve injury

b) Median nerve injury

c) Klumpke's paralysis

d) All of the above

Correct Answer - D

This is a case of complete claw hand (clawing of all fingers). It is seen in:

1. Median plus ulnar nerve injury
2. Klumpke's palsy as it involves root value of ulnar nerve & medial root of median nerve → T1 & C8.

375. Isthmus of thyroid gland lies at which level?

a) C2

b) C4

c) C5

d) C7

Correct Answer - D
Isthmus of thyroid gland lies at C7 level

376. Inferior thyroid artery is a branch of?

a) Thyrocervical trunk

b) External carotid artery

c) Internal carotid artery

d) None of the above

Correct Answer - A

Thyrocervical trunk gives three branches (SIT):

S-Suprascapular artery

I- Inferior thyroid artery

T-Transverse cervical artery

377. Dorello's canal transmits in tip of temporal bone

a) Middle maningeal artery

b) Mandibular nerve

c) Superior alveolar branch of maxillary

d) Abducent nerve

Correct Answer - D

Dorello canal is an opening to cavernous sinus that transmit abducent nerve underneath the superior petrosal sinus.

378. Structure derived from first pharyngeal arch:

a) Levator palatini

b) Buccinator

c) Stylohyoid

d) Anterior belly of digastric

Correct Answer - D

Answer D. Anterior belly of digastric

MESODERMAL DERIVATIVES OF PHARYNGEAL ARCHES

Pharyngeal arch	Muscular contributions	Skeletal contributions	Nerve
Ist (also called "mandibular arch")	<ul style="list-style-type: none"> • Mylohyoid • Muscles of mastication • Anterior belly of digastric • Tensor veli palatini • Tensor tympani • Stapedius • Stylohyoid 	<ul style="list-style-type: none"> • Maxilla • Zygomatic bone • part of temporal and vomer, sphenoid, mandible • Meckel's cartilage:- Malleus, incus • Anterior ligament of malleus • sphenomandibular ligament • Reichert's cartilage, stapes (except footplate) 	Mandibular division of Trigeminal Nerve (V3).

IIInd (also called the "hyoid arch")	<ul style="list-style-type: none"> • Posterior belly of digastric • Facial expression muscles 	<ul style="list-style-type: none"> • Styloid process • Stylohyoid ligament • Smaller cornu of hyoid • Superior part of body of hyoid 	Facial
IIIrd	<ul style="list-style-type: none"> • Stylopharyngeus 	<ul style="list-style-type: none"> • Greater cornu of hyoid • Lower part of body of hyoid 	Glossopharyngeal
IVth	<ul style="list-style-type: none"> • Pharyngeal muscles • Cricothyroid 	<ul style="list-style-type: none"> • Cartilage of larynx except arytenoids • superior parathyroids, epiglottic cartilage 	Superior laryngeal branch of Vagus
VIth	<ul style="list-style-type: none"> • Intrinsic muscles of larynx (except cricothyroid) 	<ul style="list-style-type: none"> • Arytenoid cartilages of larynx 	Recurrent laryngeal nerve (branch of vagus)

379. Joint involved in movement of head from left to right.

a) Atlanto axial

b) Atlanto occipital

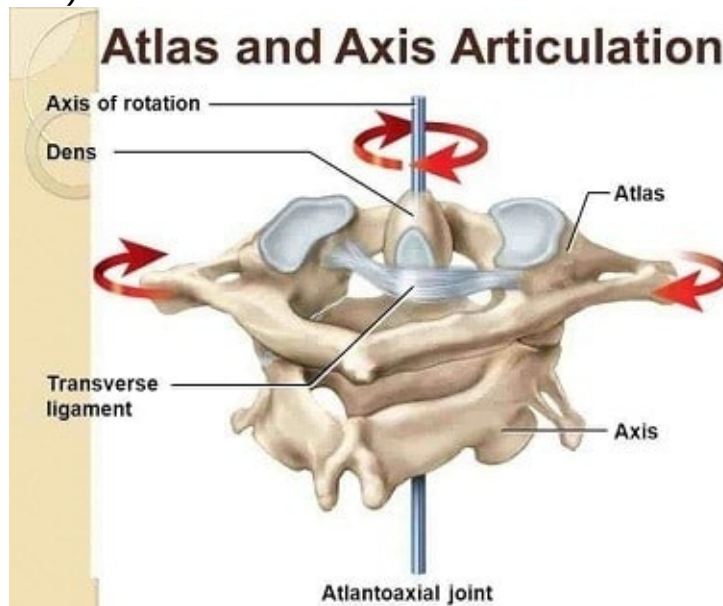
c) C2- C3 Joint

d) C3- C4 Joint

Correct Answer - A

Answer A. Atlanto axial

- Atlanto-occipital (between skull and C1) joint permit nodding of head (as when indicating approval or YES) and Atlanto-axial joint permits the head to be turned from side to side (as indicating disapproval or NO).



380. Which of the following exocrine glandular ducts are not obstructed in cystic fibrosis:

a) Pancreas

b) Lung

c) Sweat gland

d) All of above

Correct Answer - C

Answer C. Sweat gland

Most CF patients have 3 distinct abnormal characteristics:

- The ducts of the mucus-secreting glands are obstructed due to an increase in viscosity of these secretions leading to glandular dilatation and destruction.
- CF patients are prone to chronic bacterial colonization and infections.
- The sweat glands are not obstructed in CF patients because in serous glands such as sweat glands there are abnormal concentrations of inorganic ions, rather than glandular obstruction with thick mucus.
- The quantitative pilocarpine iontophoresis sweat test is a uniformly accepted method for diagnosing CF. The sweat gland ducts must be patent for this test.
- Obstruction of airways leads to bronchiectasis and atelectasis; pancreatic duct obstruction leads to pancreatitis and malabsorption; and plugging of bile ducts leads to obstructive jaundice.

381. Which of the following is not a support of the uterus?

a) Urogenital diaphragm

b) Pelvic diaphragm

c) Perineal body

d) Rectovaginal septum

Correct Answer - D

Ans: D. Rectovaginal septum

- Rectovaginal septum is not a support of the uterus.

Supports of the Uterus

Primary Supports

Secondary Supports

(Formed by peritoneal Ligaments)

Muscular or Active support:

Pelvic diaphragm°

Perineal body°

Urogenital diaphragm°

Broad ligament

Uterovesical fold of peritoneum

Rectovaginal fold of peritoneum

Ligamentous (Fibromuscular or Mechanical) support:

- Transverse cervical ligaments of Mackenrodt or Cardinal

Uterosacral ligament°

Round ligament of uterus°

Pubocervical ligament°

382. All of the following have general visceral efferent fibers except:

a) Facial nerve

b) Olfactory nerve

c) Oculomotor nerve

d) Glossopharyngeal nerve

Correct Answer - B

Ans: B. Olfactory nerve

Olfactory nerve does not have general visceral efferent fibers.

Functional Division of Cranial Nerve Nuclei

Sensory / Afferent

- **1. General Somatic**
- Sensory nucleus of trigeminal (descending & mesencephalic nucleus of V^h)
- Receive sensation of face

2. General Visceral

- Nucleus of tractus solitaries.
- Receive taste from tongue &

Motor / Efferent

1. General

- Supply striated muscle derived from somites & in tongue & eye movements i.e.
- Hypoglossal nucleus of 12th
- Oculomotor nucleus of 3rd
- Trochlear nucleus of 4th
- Abducent nucleus of 6th

2. General

- Edinger Westphal nucleus of 3rd
- Superior salivatory nucleus of 7th
- Inferior salivatory nucleus

- 3. Special somatic**
- **4 vestibular nucleus**
 - **2 cochlear nucleus**
 - Receive stimuli from ear

of 9th

- Dorsal motor nucleus of 10th (Vagus)

3. Special Visceral or Branchial component

- Innervate muscles derived from branchial arches i.e.
- **Masticatory nucleus** of 5th
- **Facial nucleus of 7th**

383. Which of the following structures are not involved in development of diaphragm?

a) Somatic body wall

b) Septum transversum

c) Pleuroperitoneal membrane

d) Pleuropericardial membrane

Correct Answer - D

Ans: D. Pleuropericardial membrane

Pleuropericardial membrane:

- Supradiaphragmatic structure.
- Not involved in formation of diaphragm.

Development of Diaphragm:

- Septum transversum - Central tendon.
- Pleuroperitoneal membranes → Small intermediate muscular portione.
- Mesentery of esophagus → Crurae.
- Body wall → Peripheral muscular diaphragm.
- Cervical myotomes (muscular input).

384. Parasympathetic nervous system comprises of:

a) Cranial nerves III, V VII, X and sacral nerves S1, S2, S3, S4, S5

b) Cranial nerves III, VII, IX, X and sacral nerves S2, S3, S4

c) Cranial nerves V, VII, IX, X and sacral nerves S2, S3, S4

d) Cranial nerves III, V VII, X and sacral nerves S2, S3, S4

Correct Answer - B

Ans: B. Cranial nerves III, VII, IX, X and sacral nerves S2, S3, S4

(Ref Gray's 40/ep235; Ganong 25/ep257, 24/ep2571)

- Parasympathetic flow is cranio-sacral, carried by cranial nerves III, VII, X, X & sacral nerves S2, S3, S4.

385. Nerve supply of supinator is similar to which of the following muscle

a) Brachialis

b) Brachioradialis

c) Extensor digitorum

d) Pronator quadratus

Correct Answer - C

Ans: C. Extensor digitorum

- Here 2 answers are more probable for right answers.
- **Extensor digitorum > Brachioradialis.**
- Supinator, extensor digitorum (option c) and brachioradialis (option b) are supplied by radial nerve.
- Extensor digitorum as both supinator & extensor digitorum - Supplied by posterior interosseous nerve.
- Posterior interosseous nerve - Branch of radial nerve.
- Brachioradialis - Directly supplied by radial nerve.

386. Tensor fascia lata is supplied by

a) Superior gluteal nerve

b) Inferior gluteal nerve

c) Nerve to quadratus femoris

d) Sciatic nerve

Correct Answer - A

Ans: A. Superior gluteal nerve

Tensor fasciae latae:

- **Origin:** Outer lip of iliac crest, anterior superior iliac spine.
- **Insertion:**
- Iliotibial tract.
- Attached below to Clercy's tubercle on lateral tibial condyle.
- **Nerve supply:**
- Superior gluteal nerve
- **Actions:**
- Abducts & medially rotates thigh - Via iliotibial tract extending knee.
- Helps to maintain erect attitude.

387. True about renal arterial system

a) Branches are end arteries

b) Anastomosis is at Interlobar arteries

c) Anastomosis is in arcuate branches

d) Blood supply in medulla is greater than cortex

Correct Answer - A

Ans: A - Branches are end arteries

- [Ref: Keith Moore Sth/e p. 309; Gray's 3gh/e p. 276-77; Last Anatomy LLth/e p. 287)

Blood supply of kidney:

- Each kidney is supplied by renal artery.
- Renal artery - Branch of abdominal aorta.
- Drained by renal vein to IVC.

Vascular segments:

- 5 in each kidney.
- Posterior, apical, upper anterior, middle anterior & lower.
- Branches of renal artery are end arteries.
- Thus no anastomosis in renal arterial system.

388. Which of the following is derived from ectoderm

a) CNS

b) Gall bladder

c) Spleen

d) Respiratory tract

Correct Answer - A

Ans: A. CNS

Derivatives of ectoderm:

- Brain & CNS
- Neural Crest
- Adrenal Medulla
- Pharyngeal clefts
- Oligodendrocytes
- Lens (from surface E-)
- Iris muscles (Sphincter & dilator pupillae)
- Epithelium of cornea, conjunctiva outer
- Lids
- Renal pigment epithelium
- Sensory retina
- Membranous Labyrinth

389. Rotter's node is

a) Interpectoral nodes

b) Internal mammary LN

c) Supraclavicular LN

d) Infraclavicular LN

Correct Answer - A

Ans: A Interpectoral nodes

[Ref AICC cancer staging manual Vol. I p. 224]

- Interpectoral (Rotter's) lymph nodes - Small interpectoral lymph nodes located between pectoralis major & pectoralis minor muscles.

390. Structure passing deep to sacrococcygeal ligament [through sacral hiatus] are all except

a) S5 nerve

b) Coccygeal nerve

c) Filum terminale

d) Internal pudendal artery

Correct Answer - D

Ans: D Internal pudendal artery

- IRef. Textbook of human anatomy Part-3 p. 811
- **Structures passing through sacral hiatus (deep to sacrococrygeal ligament) are :-**
- 5th sacral nerve
- Coccygeal nerve
- Filum terminale

391. Rotter's lymph nodes are found between

a) Serratus anterior & Trapezius

b) Deltoid & Pectoralis major

c) Pectoralis major and Pectoralis minor

d) Latissimus dorsi and Serratus anterior

Correct Answer - C

Ans: C. Pectoralis major and Pectoralis minor

[Ref AICC cancer staging manual Vol. I p. 224]

- Rotter's lymph nodes - Small interpectoral lymph nodes located between pectoralis major & pectoralis minor muscles.
- Receive lymphatic fluid from muscles & mammary gland.
- Delivers lymphatic fluid to axillary lymphatic plexus.

392. Sacrotuberous ligament is pierced by

a) Perforating cutaneous nerve

b) Posterior femoral cutaneous

c) Superior gluteal nerve

d) Sciatic nerve

Correct Answer - A

Ans: A Perforating cutaneous nerve

Sacrotuberous ligament (STL) -

- Stabiliser of sacro-iliac joint.
 - Connects bony pelvis to vertebral column.
 - **Structure piercing via STL - Perforating cutaneous nerve.**
- Perforating cutaneous nerve:**
- Cutaneous nerve that arises from the 52 and 53 nerve roots of the sacral plexus.
 - Supplies lower medial part of buttock.

393. Mucous membrane of cervix is lined by

a) Simple squamous epithelium

b) Simple columnar epithelium

c) Stratified squamous epithelium

d) Ciliated columnar epithelium

Correct Answer - B

Ans: B Simple columnar epithelium

(Ref: Langman's Embryology 11'h/e p. 269)

- **Lining of uterine cavity** - Ciliated columnar epithelium.
- **Lining of cervical canal** - Simple (nonciliated) columnar epithelium

394. Structure piercing investing layer of deep cervical fascia in posterior triangle of neck

a) Spinal accessory nerve

b) Internal jugular vein

c) External jugular vein

d) Common carotid artery

Correct Answer - C

Ans: C. External jugular vein

(Ref: BDC Vol.-3 7th/p. 88-100)

Posterior triangle of neck -

- Posterior triangle is situated behind sternocleidomastoid muscle.

Roof:

- Formed by **investing layer of deep cervical fascia.**

Structure piercing roof of posterior triangle are:

1. Four cutaneous branches of cervical plexus, viz:

- Lesser occipital nerve (C2)
- Great auricular nerve (C2, C3)
- Transverse cervical nerve (C2, C3)
- Supraclavicular nerves (C3, C4)
- Pierces roof near middle of posterior border of sternocleidomastoid muscle.

2. External jugular vein:

- Crosses sternocleidomastoid obliquely under the cover of platysma.

395. Lining epithelium of vagina is

a) Squamous epithelium

b) Columnar epithelium

c) Transitional epithelium

d) Secretory epithelium

Correct Answer - A

Ans: A Squamous epithelium

(Ref: Ramesh Babu p. 24]

- Vaginal mucous membrane is lined by nonkeratinized stratified squamous epithelium.

396. Sacral-teratoma/sacroccocygeal teratoma is a derivative of

a) Primitive streak

b) Ectoderm

c) Hypoblasts

d) Cranial neuropore

Correct Answer - A

Ans: A Primitive streak

(Ref: Textbook of Human embryology 8th/e p.671)

Gastrulation & Hensen's node:

- In 2nd week - Gastrulation occurs ---> Establishes 3rd germ layer (mesoderm).
- Gastrulation begins with primitive streak formation in caudal region of epiblast.

Primitive node or Hensen's node or primitive knot:

- Thickening formed at cranial end of primitive streak.

Sacroccocygeal formation:

- Failure of Hensen's node to regress can lead to sacroccocygeal formation.
- Incomplete primitive streak regression → leaves caudal remnant → Sacroccocygeal teratoma.
- Arise from residual to totipotential cell rests (Hensen's node).
- Sacroccocygeal teratoma demonstrates tissue derived from all three cell layers.
- Contain varying proportions of mature & immature elements.

397. Tongue muscles are derived from

a) Lateral plate mesoderm

b) Occipital myotome

c) Intermediate mesoderm

d) Cervical myotome

Correct Answer - B

Ans: B Occipital myotome

(Ref: BDC 6th/eVol. III p. 269-270)

Development of the tongue:-

I. Epithelium:

- Ant 2/3 -- lingual swellings of 1st arch and tuberculum impar.
- Post 1/3 -- large dorsal part of hypobranchial eminence, i.e, 3rd arch.
- Posterior most part -- small dorsal part of the hypobranchial eminence, i.e. 4th arch.

II. Muscles:

- **From occipital myotomes except palatoglossus which is derived from the 6th arch.**

398. Froment's sign is due to

a) Ulnar nerve injury

b) Median nerve injury

c) Radial nerve injury

d) Intercostobrachial nerve injury

Correct Answer - A

Ans: A Ulnar nerve injury

(Ref: Maheshwari 4h/e p. 65)

Ulnar nerve injury:

- Adductor pollicis will be paralysed.
- Shows 'Froment's sign' or the 'book test'.

Procedure:

- The patient is asked to grasp a book between the thumb and index finger. Normally, a person will grasp a book firmly with the thumb extended, taking full advantage of the adductor pollicis and the first dorsal interosseous muscles.
- Patient will hold the book by using the flexor pollicis longus (supplied by the median nerve) in place of the inter-phalangeal joint of the thumb.
- This becomes more pronounced if the examiner tries to pull the book out while the patient tries to hold it.

399. To look right-left which joint is used

a) Atlanto-axial joint

b) Atlanto-occipital joint

c) Occipito-axial joint

d) C6-C7 articulation

Correct Answer - A

Ans: A. Atlanto-axial joint

- Movements permitted at atlanto-axial joints are side-to-side rotation of head (looking towards right-or left).

400. Inversion and eversion of foot occur at which joint

a) Subtalar

b) Tibiotalar

c) Inferior tibiofibular

d) Ankle

Correct Answer - A

Ans: A Subtalar

[Ref: BDC 7/e Vol. II p. 164 & VoL II 5h/e p. 162).

- Following joints take part in eversion and inversion :-
- **Principal joints:** Subtalar, talo-calcaneo-navicular.
- **Accessory joints:** Calcaneocuboid, talonavicular.

401. Medial rotator of thigh [hip joint] is

a) Gluteus maximus

b) Obturator externus

c) Obturator internus

d) Gluteus minimus

Correct Answer - D

Ans: D Gluteus minimus

[Ref BDC Vh/eVoL II p. 150 6 Vol. II Sth/e p. 150].

Medial rotation of hip joint:

- Tensor fasciae latae.
- Anterior fibres of glutei medius & minimus.

402. To look right & left [side to side movement] which type of joint is involved

a) Ellipsoid joint

b) Pivot joint

c) Saddle joint

d) Hinge joint

Correct Answer - B

Ans: B. Pivot joint

- Right to left movement occurs at atlanto-axial joint which is a pivot joint.

403. Pretrematic nerve of 1st pharyngeal arch is

a) Mandibular nerve

b) Trigeminal nerve

c) Glossopharyngeal nerve

d) Chorda-tympani

Correct Answer - D

Ans: D. Chorda-tympani

[Ref. Textbook of Human embryology 9th/e p. 712]

- **Nerve receiving branch from nerve of succeeding arch - Pre-trematic nerve.**
- **1st & 2nd pharyngeal arch.**
- Nerve of arch itself - Post-trematic nerve.
- Each arch is supplied by cranial nerve:
1st arch:
- Mandibular branch of trigeminal (Pretrematic nerve is chorda tympani branch of facial nerve).
- **2nd arch:**
- Facial nerve (Pretrematic nerve is typanic branch ofglossopharyngeal nerve)

404. Rhomboids major is inserted on ?

a) Medial border of scapula

b) Lateral border of scapula

c) Inferior angle of scapula

d) Intertubercular groove of humerus

Correct Answer - A

Ans. is 'a' i.e., Medial border of scapula

(Ref: Garg 4Uh/e p. 803, 810-812))

Origin:

- Spinous processes of T2 to T5 vertebrae

Insertion

- Medial border of the scapula, inferior to the insertion of rhomboid minor muscle.

405. Insertion of levator scapulae is ?

a) Lateral border of scapula

b) Suprolateral part of scapula

c) Superior part of medial scapula border

d) Inferior angle of scapula

Correct Answer - C

Ans. is 'c' i.e., Superior part of medial scapula border

[Ref Rockwood, Charles A.; Matsen, (2009). The shoulder, Vol. 1]

Origin:

- Posterior tubercles of transverse processes of C 1 - C4 vertebrae.

Insertion:

- Superior part of medial border of scapula

406.

Coracohumeral ligament is the degenerated part of ?

a) Biceps brachii

b) Coracobrachialis

c) Pectoralis minor

d) Latissimus dorsi

Correct Answer - C

Ans. is'c'i.e., Pectoralis minor

- (Ref: Clinical anatomy p. 101)
- Coracohumeral ligament extends from lateral margin of root of coracoid process to greater tuberosity of humerus.
- Morphologically degenerated part of the pectoralis minor.

407. Which muscle steadies the clavicle during movement of shoulder ?

a) Pectoralis major

b) Latissimus dorsi

c) Subclavius

d) Serratus anterior

Correct Answer - C

Ans. is'c'i.e., Subclavius

(Ref: Clinical anatomy j'd/e p. 1367)

- Subclavius steadies the clavicle during movements of shoulder.

408. Lymphatics from the upper limb drain into which group of axillary nodes?

a) Anterior group

b) Lateral group

c) Central group

d) Posterior group

Correct Answer - B

Ans. is 'b' i.e., Lateral group

[Ref: BDC 4h/e Vol. I p. 57-58]

Lateral group:

- Lie along the upper part of the humerus, medial to the axillary vein.
- Receive lymph from upper limb.

409. What is attached to the superior nuchal line?

a) Trapezius

b) Scalenus anticus

c) Coracobrachialis

d) Biceps Brachii

Correct Answer - A

Ans. is'a'i.e., Trapezius

[Ref: Snell's th/e p. 3a2]

Muscles attached to superior nuchal line

- Occipitalis muscle,
- The splenius capitis muscle
- Trapezius muscle,
- Sternocleidomastoid muscle

410. Extensor carpi Radialis longus is crossed by which of the following two muscles ?

a) Abductor Pollicis Longus and Extensor Pollicis brevis

b) Extensor digitorum and extensor indicis

c) Abductor Pollicis Longus and Extensor Indicis

d) Brachioradialis and Extensor digiti minimi

Correct Answer - A

411. Suboccipital nerve is?

a) C1 ventral ramus

b) C2 ventral ramus

c) C1 dorsal ramus

d) C2 dorsal ramus

Correct Answer - C

Ans: C. C1 dorsal ramus

(Ref: BDC 5th/e Vol. III p. 871).

- The suboccipital nerve is the dorsal primary ramus of the first cervical nerve (C1).
- It exits the spinal cord between the skull and the first cervical vertebra, the atlas.
- It lies within the suboccipital triangle along with the vertebral artery, where the artery enters the foramen magnum

412. Median nerve supplies which branch to the brachial arter -

a) Sensory branch

b) Sympathetic branch

c) Motor branch

d) None

Correct Answer - B

Ans. is'b'i.e., Sympathetic branch

Ref: Gray's Anatomy 39,/el

- 'Median nerve supplies vascular branches to the brachial artery in the arm.
- These fibres are sympathetic fibres.
- Median nerve has no sensory or cutaneous branch in the arm.
- Only branches it gives off in the arm are sympathetic branches to the brachial artery.

413. Greater cornua of the hyoid bone fuses with the body at what age ?

a) 15 years

b) 25 years

c) 10 years

d) 35 years

Correct Answer - B

Ans. is'b'i.e., 25 years

- Time of fusion of greater cornua of hyoid - 25 years with the body
- Time of fusion of lesser cornua = 35-40 years

414. Which of the following structure passes through the triangular interval of the arm?

a) Radial nerve

b) Axillary nerve

c) Median nerve

d) Ulnar Nerve

Correct Answer - A

Ans. is 'a' i.e., Radial nerve

(Ref:' Gray's anatomy for students. Elsevier/Churchill Livingstone p. 650]

Lower triangular space of arm - Contents:

Boundaries:

- Superior: Teres major
- Medial: Long head of tricep
- Lateral: Shaft of humerus

Contents:

- Radial nerve
- Profunda brachii vessels.

415. Which of the following is true about longus colli?

a) Origin is in the occiput

b) Extensor of the neck

c) Nerve supply is from C2 -C6

d) Inserts on C3-C6

Correct Answer - C

Ans. is 'c'i.e., Nerve supply is from C2 -C6

[Ref: Dalley AF, Agur AM. Clinically Oriented Anatomy, Sixth Edition. Lippincott Williams).

Longus Colli:

- Situated on the anterior surface of vertebral column, between the atlas and the 3rd thoracic vertebra.

416. Tragus is supplied by?

a) Lesser occipital nerve

b) Auricular branch of vagus

c) Greater auricular nerve

d) Auriculotemporal nerve

Correct Answer - D

Ans. is'd'i.e., Auriculotemporal nerve

- "The auriculotemporal nerve supplies the majority of lateral portion of ear including tragus and crux of helix".

417. Embryo develops from ?

a) Inner cell mass

b) Trophoblasts

c) Outer cell mass

d) None of the above

Correct Answer - A

Ans. is'a'i.e., Inner cell mass

[Ref Textbook of embryology p. 24)

- As the morula enters the uterine cavity, uterine fluid diffuses through zona pellucida and fills small intercellular gaps between blastomeres, and morula is converted to blastocyst.
Embryoblast :
- A group of centrally located cells of inner cell mass and later give rise to tissues of the embryo proper.

418. Optic vesicle is derived from ?

a) Neuroectoderm

b) Surface ectoderm

c) Endoderm

d) Mesoderum

Correct Answer - A

Ans. is'a'i.e., Neuroectoderm

(Ref Indo Khurana ernbryology p. 268)

Formation of optic cup

- An outgrowth from prosencephalon forms optic vesicle (neuroectodermal structure).
- Proximal part of optic vesicle becomes constricted and elongated to form optic stalk.

419. Development of the urinary bladder is from?

a) Urogenital Sinus

b) Paramesonephric Duct

c) Metanephric Blastema

d) Proctodaeum

Correct Answer - A

Ans. is 'a' i.e., Urogenital Sinus

[Ry' Inderbir Singfi Human Embryology Sth/e p. 246]

- The urinary bladder (except trigone) is derived from vesicourethral canal, cranial part of urogenital sinus (endodermal).
- Trigone is derived from absorbed part of Wolffian duct/mesonephric duct (mesodermal).

420. Distal muscles of the hand needed for fine work are controlled by -

a) Radial nerve

b) Median nerve

c) Ulnar nerve

d) Axillary nerve

Correct Answer - C

Ans. is'c'i.e., Ulnar nerve

(Ref: Snell's th/e p. 354)

- Ulnar nerve is also known as musicians nerve as it is needed to carry out fine and precision movements of the hand.

421. Protoplasmic astrocytes are located in ?

a) Gray matter

b) White matter

c) Inside blood vessels

d) Inside neurons

Correct Answer - A

Ans. is'a'i.e., Gray matter

[Ref: Clinical neurology 4h/e p. 7111

There are following types of astrocytes :

- Protoplasmic Astrocytes
- They are located in gray matter in close association with neurons.
- They provide nutrients, assist in metabolism and help in formation of blood-brain-barrier.

422. Nerve supply of latissimus dorsi -

a) Radial nerve

b) Long thoracic nerve

c) Thoracodorsal nerve

d) Axillary nerve

Correct Answer - C

Ans. is'i.e., Thoracodorsal nerve

(Ref. Gray's 3rd/e p. S46)

- Thoracodorsal nerve (C6-8) is a branch of posterior cord of brachial plexus that supplies the latissimus dorsi muscle.
- Also known as the nerve to latissimus dorsi.

423. Infundibulum develops from ?

a) Floor of lateral ventricle

b) Floor of 4th ventricle

c) Floor of third ventricle

d) Rhombencephalon

Correct Answer - C

Ans. is 'c' i.e., Floor of third ventricle

(Ref: Textbook of Neuroanatomy p. 112)

- The infundibulum of the diencephalon is a downward evagination of the floor of the third ventricle.
- As the infundibulum grows down, it meets an ectodermal diverticulum of the oral cavity, known as Rathke's pouch.

424. Visual center is present in?

a) Parietal lobe

b) Occipital lobe

c) Frontal lobe

d) Temporal Lobe

Correct Answer - B

Ans. is 'b' i.e., Occipital lobe

(Ref: BDC 6h/e Vol. III p. 421-425)

- Occipital lobe has the following areas related to vision

Primary visual cortex (strike area, area 17):

- It is present in medial surface of occipital lobe on upper lip and lower lip of calcarine sulcus.

425.

In case of Blockade of 2nd part of axillary artery blood supply to upper limb is maintained by which anastomosis -

a) Dorsal scapular anastomosis

b) Ventral scapular anastomosis

c) Circle of Willis

d) Anastomosis around internal thoracic artery

Correct Answer - A

Ans. is'a'i.e., Dorsal scapular anastomosis

(Ref: Clinical anatomy 3d/e p. 756)

Dorsal Scapular Anastomosis:

- This anastomosis occurs connects the 1st part of subclavian artery to the third part of axillary artery providing an alternate route of flow of blood in case of occlusion anywhere within the subclavian and axillary artery.

426. Proprioception is lost when?

a) Posterior part of spinal cord is injured

b) Lateral part of spinal cord is injured

c) Anterior part of spinal cord is injured

d) None

Correct Answer - A

Ans. is'a'i.e., Posterior part of spinal cord is injured

[Ref: Guyton 12'h/e p. 573]

- Posterior part of spinal cord consists of fasciculus gracilis and fasciculus cuneatus which carry the sensations of and vibration to the brain.
- They also carry fine touch and kinesthesia.

427. Proprioception is carried by which fibers?

a) Fasciculus cuneatus and fasciculus gracilis

b) Anterior spinothalamic tract

c) Lateral spinothalamic tract

d) Spinocerebellar tract

Correct Answer - A

Ans. is'a'i.e., Fasciculus cuneatus and fasciculus gracilis

(Ref: Guyton 12th/e p. 573)

- Posterior column (Dorsal column) (Fasciculus Gracilis and Fasciculus Cuneatus) carries
- Proprioception (Position of body or limb, position of joint)
- Vibration
- Fine touch (two point discrimination, topognosis, stereognosis).
- Kinesthesia

428. Stellate ganglion is seen in?

a) Cerebellum

b) Mid brain

c) Medulla oblongata

d) Near lower cervical spine

Correct Answer - D

Ans. is 'd' i.e., Near lower cervical spine

[Ry' Gray's 38h/e p. 13031

- The stellate ganglion (or cervicothoracic ganglion) is a sympathetic ganglion formed by the fusion of the inferior cervical ganglion and the first thoracic ganglion.
- Stellate ganglion is located at the level of C7, anterior to the transverse process of C7 and the neck of the first rib, superior to the cervical pleura and just below the subclavian artery.

429. Association fibers include all of the following except?

a) Corona Radiata

b) Arcuate fasciculus

c) Cingulum

d) Uncinate fasciculus

Correct Answer - A

Ans. is'a'i.e., Corona Radiata

(Ref Gray's Anatomy p. 411)

White matter of cerebrum hemisphere is divisible into 3 fiber systems :-

Association fibers:

- Connect the one functional area of one cerebral hemisphere to other in the same cerebral hemisphere.
- .. Cingulum
- 2.. Superior longitudinal fasciculus
- 3.. Inferior longitudinal fasciculus
- 4.. Uncinate fasciculus
- 5.. Arcuate fasciculus
- 6.. Fornix
- 7.. Occipitofrontal fasciculus

430. Dermatome supplying the middle finger is -

a) C6

b) C7

c) C8

d) T1

Correct Answer - B

Ans. is 'b' i.e., C7

(Ref: BDC Sth/e Vol. 1 p. 68).

- Thumb - C6
- Ring middle & index finger - C7
- Little finger - C8.

431. True about vagal nuclei are all except?

a) There are 4 vagal nuclei

b) They are found in the floor of 4th ventricle

c) Nucleus Ambiguus is a vagal nucleus

d) Spinal trigeminal nucleus is not a vagal nucleus

Correct Answer - D

Ans. is'd'i.e., Spinal trigeminal nucleus is not a vagal nucleus

(Ref: 'Functional and chemical anatomy of the afferent vagal system'. Autonomic Neuroscience. 85 (I-3): I-17.)

- The vagus nerve includes axons which emerge from or converge onto four nuclei of the medulla.
- They are present deep in the medulla in the floor of the 4th ventricle.

432. Artery of Adamkiewicz is related to?

a) Hand

b) Penis

c) Brain

d) Spinal Cord

Correct Answer - D

Ans. is'd'i.e., Spinal Cord

[Ref. Moore, Keith; Anne Agur (2007). Essential Clinical Anatomy, Third Edition. Lippincott Williams (t Wilkins. p. 29B)

- The artery of Adamkiewicz, also known as the great anterior radiculomedullary artery or arteria radicularis anterior magna, is the name given to the dominant thoraco-lumbar segmental artery that supplies the spinal cord.

433. Posterior longitudinal ligament continues as?

a) Apical ligament

b) Alar ligament

c) Membrana tectoria

d) Transverse ligament

Correct Answer - C

Ans. is'c'i.e., Membrana tectoria

[Ref: Nigel Palastanga; Roger W. Soames (2012). Churchill Livingstone, ed. Anatomy and Human Movement: Structure and Function.]

- The Posterior longitudinal ligament is situated within the vertebral canal, and extends along the posterior surface of the bodies of the vertebrae.
- It starts from the body of the axis, where it is continuous with the membrana tectoria and continues to the sacrum.

434. Sensory supply of the palm is from which nerves -

a) Median nerve and Radial nerve

b) Radial nerve and ulnar nerve

c) Ulnar nerve and Median nerve

d) Musculocutaneous nerve and Radial nerve

Correct Answer - C

Ans. is 'c' i.e., Ulnar nerve and Median nerve

(Rel BDC 5^h/e VoL I p. 108-111)

On Palm side:

- Lateral 2/3 of the palm and lateral three and half fingers → Median nerve.
- Medial 1/3 of the palm and medial one and half fingers → Ulnar nerve.

435. Which of the following is true about anatomy of the cerebellum?

a) Globose cells are present in the roof

b) Vermis is present in the midline

c) Flocculonodular lobe is concerned with smoothing and coordination of movements

d) Dentate nucleus is the medial most nucleus

Correct Answer - B

Ans. is 'b' i.e., Vermis is present in the midline.

(Ref: Ganong 23d/e p. 255)

- 'The vermis is a midline structure that connects the two cerebellar hemispheres.'
- 'Dentate nucleus is the lateral most nucleus.'
- 'Spinocerebellum and not flocculonodular lobe is concerned with smoothing and coordination of movements'
- 'Globose cells are a part of deep cerebellar nuclei and are present deep inside the substance of cerebellum.'

436. Cortex to medulla ratio in adults of the kidney is?

a) 35-45%

b) 50-60%

c) 60-70%

d) 15-20%

Correct Answer - A

Ans. is 'a' i.e., 35-45%

- As the age progresses the amount of cortex in the kidney decreases more compared to the medulla and hence the ratio decreases.
- In children the cortico medullary ratio is high, almost to the extent of 1:1 (around 50%).
- In healthy adults it is 35-45%.

437. Contraction of Detrusor muscle is mediated by?

a) S2,S3,S4

b) Vagus

c) Lumbar sympathetic supply

d) Pudendal nerve

Correct Answer - A

Ans. is'a'i.e., S2,S3,S4

[Ref: BDC dh/e Vol. II p. 375; Clinical anatomy p. 9127

- Bladder is supplied by both sympathetic and parasympathetic fibers.
- **A) Parasympathetic:**
- Preganglionic fibers arise from S2 to S4 cord segments, pass via pelvic splanchnic nerves.
- After relay in ganglion cells in pelvic plexus (inferior hypogastric plexus) and in bladder wall, postganglionic fibers supply detrusor muscle.
- Contraction of detrusor muscle is mediated by cholinergic muscarinic receptors (M3).
- Preganglionic parasympathetic neurons at S2, S3, and S4 cord segments innervating bladder form sacral micturition center.

438. Which foot bone does not have any muscle attachment?

a) Talus

b) Calcaneum

c) Navicular

d) 1st metatarsal

Correct Answer - A

Ans. is 'a' i.e., Talus

[Ref BDC 6th/e Vol. II p. 30]

- Talus is the only bone in the foot having no muscle attachment. Only ligamentous attachment.

439. Radial tuberosity provides attachment to

-

a) Brachialis

b) Biceps brachii

c) Triceps

d) Coracobrachialis

Correct Answer - B

Ans. is 'b' i.e., Biceps brachii (Ref: Elsevier's integrated anatomy Vol 2 p 30).

- An anterior, rough portion of tubercle - For insertion of tendon of biceps brachii.
- A posterior smooth portions of tubercle - Bursa interposed between tendon & bone..

440. Which of the following is present at the superior border of the pancreas ?

a) Splenic artery

b) Portal vein

c) Left Kidney

d) IVC

Correct Answer - A

Ans. is'a'i.e., Splenic artery

(Ref: BDC &/e Vol.II p. 300)

The body of pancreas has 3 borders-

- Anterior border provides attachment to the root of transverse mesocolon.
- Superior border is related to coeliac trunk, hepatic artery and splenic artery.
- Inferior border is related to superior mesenteric vessels.

441. Which of the following muscle cause hip extension and knee flexion ?

a) Semitendinosus

b) Gastrosoleus

c) Psoas major

d) Tensor Fascia lata

Correct Answer - A

Ans. is'a' i.e.. Semitendinosus

- Semitendinosus is hamstring muscle.
- Causes flexion at knee & extension at hip.

442. Normal splanchnic blood supply of the liver includes?

a) Portal vein

b) Splenic artery

c) Superior mesenteric artery

d) Inferior mesenteric vein

Correct Answer - A

Ans. is'a'i.e., Portal vein

(Ref, Gray's 4F/e p. 1163-1167)

- Liver has dual blood supply and receives 20% of its blood supply via hepatic artery (systemic) and 80% through portal vein (splanchnic).
- Portal vein is formed by union of splenic vein and superior mesenteric veins.

443. All of the following are true about the root of right lung except?

a) Azygous vein crosses anteriorly and superiorly

b) Vagus crosses it anteriorly

c) Phrenic nerve crosses it anteriorly

d) SVC is present anteriorly

Correct Answer - B

Ans 'b'i.e., Vagus crosses it anteriorly

(Ref: Snell's 7th/e p. 94; BDC 4'h/e Vol.I p. 224)

- Vagus nerve crosses both hila posteriorly.
- Azygous vein arches the hilum of right lung (azygous vein is superior to hilum)
- Phrenic nerve (on both sides) and SVC (on right side) are anterior.

444. At the superficial inguinal canal increased abdominal pressure leads to closure by approximation of crura in the opening. This defect is seen in an aponeurosis formed by which of the following muscles?

a) Fascia transversalis

b) External oblique

c) Internal oblique

d) Erector spinae

Correct Answer - B

Ans. is'b'i.e., External oblique

(Ref: BDC &/e Vol. II p. 212, 213; Ramesh Babu p. 219)

- Examiner is asking about superficial inguinal ring which is triangular defect in external oblique aponeurosis.
- Superficial inguinal ring is an anatomical structure in the anterior abdominal wall. It is a triangular shaped defect in the aponeurosis of external oblique muscle

445. Typical intercostal space has -

a) One artery

b) Two arteries

c) Three arteries

d) Four arteries

Correct Answer - C

Ans.is 'c' i.e., Three arteries

(Ref: BDC 6h/e Vol. I p. 219)

- Each of upper nine intercostal spaces have one posterior and two anterior intercostal arteries.

446. Hesselback triangle- False is?

a) Indirect inguinal hernia occurs through it

b) It is laterally bounded by inferior epigastric artery

c) it is also known as inguinal triangle

d) Inferior boundary is inguinal ligament

Correct Answer - A

Ans. is 'a' i.e., Indirect inguinal hernia occurs through it

[Ref: BDC 4n/e Vol.2 p. 50, 210]

Inguinal triangle of hesselbach:

- It is a peritoneal triangle in the posterior wall of the inguinal canal,
Boundaries
 1. Lateral- inferior epigastric artery
 2. Medial-lateral border of rectus abdominis
 3. Inferior- inguinal ligament
- Direct inguinal hernia enters the inguinal canal through this triangle, which is divided by the obliterated umbilical artery into a medial part (supravesical fossa) and a lateral part (medial inguinal fossa).

447. Supraventricular crest lies between -

a) Pulmonary orifice and atrioventricular orifice

b) Atrioventricular orifice and fossa ovalis

c) SVC and right atrium

d) Right and left coronary artery

Correct Answer - A

Ans. is 'a' i.e., Pulmonary orifice and atrioventricular orifice

(Ref: BDC 8/e Vol, I p. 253-258).

- Supraventricular crest (crista supraventricularis) or infundibulo-ventricular crest separates tricuspid (AV) orifice and pulmonary orifice, i.e. inlet and outlet parts.

448. Anorectal malformations include all of the following except?

a) Coloanal fistula

b) Rectourethral fistula

c) Imperforate anus

d) Anal Stenosis

Correct Answer - A

Ans. is'a'i.e., Coloanal fistula

- Anorectal malformations are conditions occurring due to congenital anomalies of the rectum and anus
- They include :**
- Anal stenosis
- Persistent Cloaca
- Imperforate anus
- Rectourethral or rectovesical fistula
- Rectovaginal fistula

449. Lower 1/3^d of anal canal is derived from?

a) Proctodaeum

b) Cloaca

c) Urogenital Sinus

d) Midgut

Correct Answer - A

Ans. is'a'i.e., Proctodaeum

(Ref: BDC Sh/eVol. II p. 415)

- 'The lower third of the anal canal is an ectodermal derivative and is derived from the proctodaeum.'
- Part of anal canal above pectinate line develops from dorsal part of md.odermal cloaca (primitive rectum) and part of anal canal below pectinate line develops from ectodermal proctodeum.

450. Nerve supply of cervical esophagus ?

a) Vagus

b) Left recurrent laryngeal nerve

c) Right recurrent laryngeal nerve

d) All of the above

Correct Answer - D

Ans. is d', All of the above

[Ref Clinical anatomy 3'd/e p. 2891

Nerve supply of esophagus:

- Esophagus is supplied by both parasympathetic and sympathetic fibers.
- A) Parasympathetic supply**
- It provides sensory, motor and secretomotor supply to esophagus.
- Complete parasympathetic innervation is provided by vagus nerve:-**
1. Cervical esophagus: Through both (right & left) recurrent laryngeal nerve.
 2. Upper thoracic esophagus: Through left recurrent laryngeal nerve and by direct branches from vagus nerve.
 3. Lower thoracic esophagus: Through esophageal plexus.
- B) Sympathetic supply**
- It provides sensory and vasomotor supply.
 - It is provided by T₅ to T₁₁ spinal segments.

451. Perineal body muscles include all of the following except?

a) External anal sphincter

b) Levator ani

c) Deep transverse perenei

d) Iliacus

Correct Answer - D

Ans. is 'd' i.e., Iliacus

[Ref: BDC &/e Vol. II p. 425]

- Ten muscles of perineum converge and interlace in the perineal body -
 - A) Two unpaired - (i) External anal sphincter, (ii) Fibres of longitudinal muscle coat of anal canal.
 - B) Four paired:- (i) Bulbospongiosus, (ii) Superficial transverse perenei, (iii) Deep transversus perenei, (iv) Levator ani.
- In females, sphincter urethrovaginalis is also attached here.

452. Muscles forming floor of pelvis are all except?

a) Pubococcygeus

b) Iliococcygeus

c) Ischiococcygeus

d) Iliacus

Correct Answer - D

Ans. is'd' i.e.,Iliacus.

(Ref: BDC &/eVol.IIp. 425)

- The pelvic floor is formed by the levator ani muscle which consists of three parts:-
 1. Pubococcygeus
 2. Iliococcygeus
 3. Ischiococcygeus

453. Which of the following is true about upper 1/3' of the rectum?

a) It is covered by peritoneum only anteriorly

b) It is covered by peritoneum on the front, sides and back

c) It has no peritoneal attachments

d) It is covered by peritoneum on the sides and anteriorly

Correct Answer - D

Ans. is'd' i.e., It is covered by peritoneum on the sides and anteriorly

(Ref: Basic Human Anatomy, O'Rahilly, Muller Chapter 36)

- Upper 1/3'd of rectum Covered by peritoneum on the front and sides
- Middle 1/3'r of rectum Covered by peritoneum on the sides only
- Lower 1/3"r of rectum Devoid of peritoneal attachments

454. True about relations of thoracic esophagus ?

a) Trachea posteriorly

b) Aortic arch on right side

c) Left bronchus anteriorly

d) Thoracic duct on right side

Correct Answer - C

Ans. is 'c' i.e., left bronchus anteriorly

(Ref: Snell's p. 128)

The relations of the thoracic part of the esophagus from above downward are as follows:

- Anteriorly: The trachea and the left recurrent laryngeal nerve: the left principal bronchus which constricts it; and the pericardium, which separates the esophagus from the left atrium.
- Posteriorly : The bodies of the thoracic vertebrae, the thoracic duct, the azygos veins, the right posterior intercostal arteries and at its lower end the descending thoracic aorta.
- Right side: The mediastinal pleura and the terminal part of the azygos vein.
- Left side: The left subclavian artery, the aortic arch, the thoracic duct the mediastinal pleura.

455. Which vein is found at the apex of the heart ?

a) Great cardiac vein

b) Coronary Sinus

c) Anterior cardiac vein

d) Middle cardiac vein

Correct Answer - A

Ans. is'a'i.e., Great cardiac vein

[Rel BDC 4n/e Vol. I p. 251-252; Keith Moore 4e/e p. 136-137;
Snell's 9/e p. 1211

Great Cardiac Vein:

- The great cardiac vein (left coronary vein) begins at the apex of heart and ascends along the anterior longitudinal sulcus to the base of ventricle.

456. Right hepatic vein drains which segment of the liver?

a) I

b) II

c) IV

d) VII

Correct Answer - D

Ans. is'd' i.e., VII

[Rel Gray's 4th/e p. 1163-1167; Sabatton 18th/e p. 15841

Segmental anatomy of the liver:

- Based on the distribution of portal vein and hepatic vein, Couinaud divided each physiological (functional) lobe of liver into
- 4 segments each and hence liver is divided into 8 segments.
- The physiological left lobe is composed of 4 segments designated I to IV and is supplied by left branch of hepatic artery, left branch of portal vein and drained by left hepatic duct and left hepatic vein.
- The physiological right lobe consists of segment V, VI, VII and VIII and is supplied by right hepatic artery, right branch of portal vein and drained by right hepatic duct and right hepatic vein.

457. Xiphisternum is present at what level ?

a) T5

b) T6

c) T9

d) T10

Correct Answer - C

Ans. is'c'i.e., T9

(Ref. Keithl. Moore Clinically Oriented Anatomy Ple p. 84)

- Level of xiphisternum - T9

458. Lower end of humerus ossifies from how many secondary ossification centers

a) 1

b) 2

c) 4

d) 6

Correct Answer - C

Ans. is 'c' i.e., 4

- The humerus ossifies from one primary center and 7 secondary centers
- The upper end ossifies from 3 secondary centers head (1" year) → greater tubercle (2' year) → lesser tubercle (5th year).
- The lower end ossifies from 4 secondary centers which form 2 epiphyses.
- The center (fourth center) for medial epicondyle appears at 4-6 years, forms a separate epiphysis and fuses with shaft during 20th year.

459. Sacral ala is related to

a) Ureter

b) Parasympathetic ganglion

c) Umbilical artery

d) Iliolumbar artery

Correct Answer - D

Ans. is 'd' i.e., Iliolumbar artery,

- **Ala of sacrum** is a large triangular surface either side of **sacral** base, continuous with iliac fossa (akin to adapted and joined transverse and costal processes elsewhere spine)
- The smooth medial part of the ala of sacrum is associated with the subsequent 4 structures from medial to lateral side: 1. Sympathetic chain. 2. Lumbosacral trunk. 3. Iliolumbar artery. 4. Obturator nerve.
- The ventral ramus of L5 nerve is really tight that it grooves the ala.
- The rough lateral part of the ala provides origin to iliacus muscle anteriorly and connection to the lumbosacral ligament posteriorly.

460. Ala of sacrum is not crossed by

a) Sympathetic chain

b) Iliolumbar artery

c) Obturator nerve

d) Ureter

Correct Answer - D

Ans. is 'd' i.e., Ureter

- The smooth medial part of the ala of sacrum is associated with the subsequent 4 structures from medial to lateral side: 1. Sympathetic chain. 2. Lumbo-sacral trunk. 3. Iliolumbar artery. 4. Obturator nerve.
- The ventral ramus of L5 nerve is really tight that it grooves the ala.
- The rough lateral part of the ala provides origin to iliacus muscle anteriorly and connection to the lumbo-sacral ligament posteriorly.

461. Muscular ridges [trabeculae carneae] are present in

a) Left atrium

b) Left ventricle

c) Right atrium

d) Right ventricle

Correct Answer - B:D

Ans. is `b > d' i.e., Left ventricle > Right ventricle

- As Trabeculae **carneae** are present both in right and left ventricles. But they are more prominent in left ventricle
- ACCORDING TO Essentials of Anatomy; "The inflow part of each ventricle has a rough inner, surface because of presence of numerous bundles of cardiac muscle called trabeculae **carneae**".

462. True about hemiazygos vein are all except

a) Pierces left crus of diaphragm

b) Drains esophageal vein

c) At T8 level drains into azygos vein

d) Formed by right lumbar azygos and right ascending lumbar veins

Correct Answer - D

Ans. is 'd' i.e., Formed by right lumbar azygos and right ascending lumbar veins

Hemiazygos vein:

- The hemiazygos vein originates from the left ascending lumbar vein, left renal vein, or both.
- The hemiazygos vein enters the thorax through the aortic hiatus. It then continues superiorly along the left anterior aspect of the vertebral bodies.
- Along its path the hemiazygos vein receives the lower four or five left intercostal veins. It also frequently receives the accessory hemiazygos vein.
- Function: The hemiazygos vein helps to drain the left mediastinum and left lower esophagus.
- The hemiazygos vein crosses from left to right at approximately the level of T9 and terminates by emptying into the azygos vein.

463. Third coronary artery is -

a) Right coronary artery

b) Left coronary artery

c) Conus artery

d) Anterior interventricular artery

Correct Answer - C

Ans. is 'c' i.e., Conus artery

- Third coronary artery is seen only in 50% of human hearts. It is also called conus artery. The **conus artery** is a small early branch off the right coronary artery (RCA) circulation.

464. Which is derived from thoracolumbar fascia -

a) Medial arcuate ligament

b) Lateral arcuate ligament

c) Lacunar ligament

d) Cruciate ligament

Correct Answer - B

Ans. is 'b' i.e., Lateral arcuate ligament

- The **lateral arcuate ligament** (also **lateral** lumbocostal arch and external **arcuate ligament**) is a **ligament** under the diaphragm that arches across the upper part of the quadratus lumborum muscle. It is traversed by the subcostal nerve, artery and vein.
- It is derived from thoracolumbar fascia.

465.

Right gastric nodes drain from which part of stomach

a) Fundus

b) Greater curvature

c) Lesser curvature

d) None

Correct Answer - C

Ans. is 'c' i.e., Lesser curvature

The gastric lymph nodes consist of two sets, superior and inferior.

- The Superior Gastric Glands accompany the left gastric artery and are divisible into three groups:
 1. Upper, on the stem of the artery;
 2. Lower, accompanying the descending branches of the artery along the cardiac half of the lesser curvature of the stomach, between the two layers of the lesser omentum;
 3. Paracardial outlying members of the gastric glands, disposed in a manner comparable to a chain of beads around the neck of the stomach. They receive their afferents from the stomach; their efferents pass to the celiac group of preaortic lymph nodes.
- The Inferior Gastric Glands, four to seven in number, lie between the two layers of the greater omentum along the pyloric half of the greater curvature of the stomach.

466. Gerlach valve is present in -

a) Gall bladder

b) Nasolacrimal duct

c) Pancreatic duct

d) Vermiform appendix

Correct Answer - D

Ans. is 'd' i.e., Vermiform appendix

- **Valve of Gerlach** definition is - an inconstant fold of mucous membrane resembling a **valve** at the cecal end of the vermiform appendix.

467. Normal volume of adult testis

a) 5-10 ml

b) 10-15 ml

c) 15-20 ml

d) 25-30 ml

Correct Answer - C

Ans. is 'c' i.e., 15-20 ml

"Normal adult testicular volume is 15-20 ml, calculated by the formula :

- length x width x depth x 0.52 = volume" — Grainger.

468. All of the following are muscles of nose except

a) Procerus

b) Compressor naris

c) Depressor septi

d) Angularisoris

Correct Answer - D

Ans. is 'd' i.e., Angularisoris

- Muscles of nose :- Procerus, compressor naris, dilator naris, depressor septi.
- Muscles around mouth :- Orbicularis oris, buccinator, levatorlabii superioris, alaque nasi, zygomaticus major, levatorlabii superioris, levatorangulioris, zygomaticus minor, depressor angulioris, depressor labiiinferioris, mentalis, **risorius**.

469. Lymphatic drainage of lateral wall of nose

a) Submandibular nodes

b) Retropharyngeal nodes

c) Deep cervical nodes

d) All of the above

Correct Answer - D

Ans. is 'd' i.e., All of the above

- Lymphatic drainage of nose is BY Anterior half of nasal cavity (Both septum and lateral wall) -s Submandibular nodes
- Posterior half of nasal cavity (Both septum and lateral wall)Retropharyngeal nodes and upper deep cervical nodes.

470. Efferent fibers of amygdala are

a) Stria terminalis

b) Striavascularis

c) Lamina terminalis

d) Mosseyfibers

Correct Answer - A

Ans. is 'a' i.e., Stria terminalis

- Stria terminalis forms the efferent fibers of amygdaloid nucleus passing in the roof of inferior horn and floor of body of lateral ventricle.

471. Yolk sac is derived from

a) Hypoblasts

b) Epiblasts

c) Syncytiotrophoblast

d) None

Correct Answer - A

Ans. is 'a' i.e., Hypoblasts

- The yolk sac develops from hypoblast cells. By the end of 2nd week the lower half of primary yolk sac pinches off to form definitive yolk sac, while a second wave of hypoblast cells form inner lining of definitive yolk sac.

472.

Part of neural tube from which corpus callosum develops

a) Basal lamina

b) Alar lamina

c) Lamina terminalis

d) Basal plate

Correct Answer - C

Ans. is 'c' i.e., Lamina terminalis

- The development of the corpus callosum occurs between the 12th and 16-20th weeks of gestation.
- It begins with the genu and then continues posteriorly along the body to the splenium. The rostrum is the last part to be formed.
- Myelination of the corpus callosum occurs in the opposite direction, from the splenium forwards.
- They develop from lamina terminalis which is *cranial part of neural tube* and later lies in the anterior wall of 3rd ventricle.
- The corpus callosum, the largest of cerebral commissures, takes the form of an arch over the third ventricle.
- It connects the neocortices of both sides.

473.

Which of the following part of corpus callosum develops first

a) Dorsal part of genu

b) Ventral part of genu

c) Rostrum

d) Splenium

Correct Answer - A

Ans. is 'a' i.e., Dorsal part of genu

- During development of corpus callosum, the *dorsal part of genu* and the *body/trunk form first*. Subsequently, ventral (anterior) part of genu and then the splenium arise. Last, the rostrum develops.

474. Gene for eye morphogenesis

a) Pax-6

b) BMP-4

c) HOX-D13

d) HOX-A13

Correct Answer - A

Ans. is 'a' i.e., Pax-6

- The Pax-6 gene locus is a transcription factor for various genes and growth factors involved in eye formation. Pax-6 is a master control gene for eye morphogenesis and encodes for Paired box protein Pax-6 (also called aniridia type II protein or oculorhombin).

475. Inner ear fully developed at

a) 4 weeks

b) 10 weeks

c) 20 weeks

d) 32 weeks

Correct Answer - C

Ans. is 'c' i.e., 20 weeks

- Development of membranous internal ear is *completed by 10" weeks* and reaches its *adult size and shape by 20-22 weeks* when the cochlea is developed sufficiently.

476. Remnant of rostral neuropore is -

a) Septum transversum

b) Ligamentum teres

c) Lamina terminalis

d) Cerebellum

Correct Answer - C

Ans. is 'c' i.e., Lamina terminalis

- The cranial open end of neural tube is called as rostral (anterior) neuropore which closes on or before day 26 giving rise to lamina terminalis of brain.

477. Blood supply of spinal cord is through

a) Anterior spinal artery

b) Vertebral artery

c) Deep cervical artery

d) All of the above

Correct Answer - D

Ans. is 'd' i.e., All of the above

The vertebral arteries are the main source of blood to the [spinal cord](#). However, the following arteries branch from the vertebral arteries to directly supply the spinal cord itself:

- one anterior spinal artery
- two posterior spinal arteries
- anterior and posterior radicular arteries
- arterial vasocorona (anastomose between the spinal arteries)

The anterior and two posterior spinal arteries are direct branches of the two vertebral arteries which merge rostrally to form a single artery - the basilar artery of the Circulus arteriosus ([Circle of Willis](#)). Thus, the vertebral arteries are very important, as they serve as the primary source of blood to the brain and the spinal cord.

Similarly, the radicular arteries take origin from spinal branches of the vertebral arteries and spinal branches of ascending cervical arteries, deep cervical arteries, intercostal arteries, lumbar arteries and sacral arteries.

478.

Which of the following part of corpus callosum develops first

a) Dorsal part of genu

b) Ventral part of genu

c) Rostrum

d) Splenium

Correct Answer - A

Ans. is 'a' i.e., Dorsal part of genu

- During development of corpus callosum, the dorsal part of genu and the body/trunk form first followed by ventral (anterior) part of genu and then the splenium arise. And in Last, the rostrum develops. As a rule of thumb, the corpus callosum is formed from anterior to posterior, with the exception of anterior part of genu and rostrum.

479. Dodd's perforator is present between ?

- a) Short saphenous and femoral veins
- b) Short saphenous and great saphenous veins
- c) Great saphenous and femoral veins
- d) None of the above

Correct Answer - C

Ans. is 'c' i.e., Great saphenous and femoral veins

A. Spheno-femoral perforators (between great-saphenous and femoral vein)

1. Hunterian perforator -> In mid thigh (In adductor canal)

2. Dodd's perforator In distal thigh

B. Boyd's perforator (kee perforator) 4 Just below knee between great saphenous and posterior tibial vein.

C. Cockett Perforators (medial ankle or lower leg perforators) :
Between posterior arch vein and posterior tibial vein ?

1. Cockett I (Lower medial) - Behind and below medial malleolus

2. Cockett II (Middle medial) - Between Cockett I & III (10 cm above medial malleolus)

3. Cockett III (Upper medial) - At junction of middle and lower third of leg (15 cm from medial malleolus).

D. Lateral ankle perforator: Between short saphenous vein and peroneal vein. At junction of middle and lower third of leg.

480. Root value for nerve to Quadratus femoris ?

a) L1,L2,L3

b) L2,L3,L4

c) L₄,L₅,S₁

d) S₁, S2,S3

Correct Answer - C

Ans. C. L₄,L₅,S₁

- The nerve to quadratus femoris arises from the **anterior** divisions of the **sacral plexus**.
- It is formed from the L4-S1 nerve roots and exits the pelvis via the greater **sciatic** foramen inferior to the **piriformis muscle** and deep to the **sciatic** nerve.

481. Not attached on medial border of scapula ?

a) Serratus anterior

b) Levator scapulae

c) Rhomboides major

d) Teres major

Correct Answer - D

Ans. is 'd' i.e., Teres major

Muscles attached to scapula are :-

- Coracoid process :- Tip of the coracoid process gives origin to coracobrachialis (medially) and short head of the biceps laterally.
- The upper surface receives insertion of pectoralis minor.
- Spine of scapula and acromion process :- There is origin of Deltoid and insertion of trapezius.
- Glenoid tubercle :- Supraglenoid tubercle gives origin to the long head of biceps and infra glenoid tubercle gives origin to long head of triceps.
- Lateral border :- Origins of teres minor and teres major.
- Medial border :- Insertions of serratus anterior (anteriorly); and rhomboides major, rhomboides minor and levator scapulae (posteriorly).
- Costal (anterior) surface (origin) Subscapularis.
- Dorsal surface (origins) Supraspinatus, infraspinatus and at inferior angle latissimus dorsi.

482. Subclavian artery is divided by which muscle ?

a) Pectoralis minor

b) Teres minor

c) Scaleneus anterior

d) Trapezius

Correct Answer - C

Ans. is 'c' i.e., Scaleneus anterior

- **Scaleneus anterior muscle divides subclavian artery into three parts :?**

A) First part :

- This part is medial (proximal) to scaleneus anterior. Branches from first part are :?
 1. Vertebral artery
 2. Internal thoracic artery
 3. Thyrocervical trunk:
 1. Costocervical trunk (on left side only).

B) Second part :

- This part lies posterior to scalenus anterior. It gives origin to Costocervical trunk on right side. Costocervical trunk gives following branches:
 1. Deep cervical artery
 2. superior intercostal artery.

C) Third part :

- This part lies lateral (distal) to scalenus anterior. It gives dorsal scapular artery (sometimes dorsal scapular artery arises from transverse cervical artery, a branch of thyrocervical trunk).

483. Patent foramen ovate is due to?

a) Failure of closure of sinoatrial orifice

b) Failure of fusion of septum primum and endocardial cushion

c) Failure of fusion of septum primum and septum intermedium

d) Failure of fusion of septum primum and septum secundum

Correct Answer - D

Ans. is 'd' i.e., Failure of fusion of septum primum and septum secundum

- After birth, the foramen ovale closes by fusion of septum primum with septum secundum.
- Failure of fusion of these two septa results in patent foramen ovale.

484. Organogenesis is maximally affected in which period of gestation ?

a) 1-4 weeks

b) 4-8 weeks

c) 10-15 weeks

d) 15-20 weeks

Correct Answer - B

Ans. is 'b' i.e., 4-8 weeks

The development of a new individual in the uterus involves three phases :-

1. Pre-embryo phase or germinal phase (day 0-3 weeks).
 2. Embryo phase or embryonic period (weeks 4-8).
 3. Fetal phase (weeks 8-38).
- The embryonic period of development extends from fourth to eighth week of gestation and is also called period of organogenesis.
 - During this period the main organ systems are developed from three germinal layers. However, the function of most of them is negligible except for cardiovascular system, i.e. cardiovascular system is the earliest to function.

485. Which is the middle and large carpal bone ?

a) Scaphoid

b) Pisiform

c) Hamate

d) Capitate

Correct Answer - D

Ans. is 'd' i.e., Capitate

- Among the given options only capitate lies in middle (not lateral or medial) and it is the largest carpal bone.
- Scaphoid is lateral most bone in proximal row, pisiform is medial most bone in proximal row and hamate is medial most bone in distal row.

486. Organogenesis is maximally affected in which period of gestation ?

a) Germinal phase

b) Embryonic phase

c) Fetal phase

d) None

Correct Answer - B

Ans. is 'b' i.e., Embryonic phase

The development of a new individual in the uterus involves three phases :-

1. Pre-embryo phase or germinal phase (day 0-3 weeks).
 2. Embryo phase or embryonic period (weeks 4-8).
 3. Fetal phase (weeks 8-38).
- The embryonic period of development extends from fourth to eighth week of gestation and is also called period of organogenesis.
 - During this period the main organ systems are developed from three germinal layers. However, the function of most of them is negligible except for cardiovascular system, i.e. cardiovascular system is the earliest to function.

487. Rib ossification center first appears in which rib ?

a) 1st

b) 12th

c) 6th

d) 3rd

Correct Answer - C

Ans. is 'c' i.e., 6th

Each rib (except for 11th & 12th) is ossified from four centres :-

- One primary centre-->for body
- Three epiphyseal (secondary)centres for :-**
 1. Head
 2. Articular part of tubercle
 3. Non articular part of tubercle
- Ossification begins near the angle toward the end of 2nd month (around 8th week) of fetal life, and is seen first in 6th and 7th ribs.
- The epiphyses for the head and tubercle make their appearance between 16th and 20th years, and are united to the body about the 25th year.

488. True about erector spinae are all except ?

a) Causes flexion of trunk

b) Causes lateral flexion and rotation of trunk

c) Includes iliocostalis, longissimus and spinalis

d) All are correct

Correct Answer - A

Ans. is 'a' i.e., Causes flexion of trunk

- **Erector spinae** is group of muscles of back which extends the vertebral column.
- It is paired formed of 3 other muscles and tendons and runs more or less vertically.
- **From medial to lateral it includes -**
 - Spinalis
 - Longissimus
 - Iliocostalis
- **Function:**
 - On bilateral contraction it causes extension of vertebral column.
 - On unilateral contraction it causes lateral flexion (bending) and rotation to ipsilateral side.

489. Spinal cord and nerve roots are supplied by ?

a) Anterior spinal artery

b) Posterior spinal artery

c) Ascending cervical artery

d) All of the above

Correct Answer - D

Ans. is D i.e., All of the above

Anterior and posterior spinal arteries supply spinal cord, but not spinal nerve roots.

- Spinal nerve roots are supplied by *radicular arteries* which are segmental branches of vertebral, ascending cervical, deep cervical, intercostal and sacral arteries.

Blood supply of spinal cord

1. The spinal cord receives its blood supply from :

- The anterior spinal artery
 - Two posterior spinal arteries
 - In addition to these channels the pia mater covering the spinal cord has an arterial plexus (called the arterial vasocorona) which also sends branches into the substance of the cord.
2. The main source of blood to the spinal cord is from the vertebral arteries (from which the anterior and posterior spinal arteries take origin)
- However, the blood from the vertebral artery reaches only up the cervical segments of the cord.
 - Lower down the spinal cord receive blood through radicular arteries that .These arise form spinal branches of the vertebral, ascending cervical, deep cervical, intertcostal, lumbar and sacral arteries



490. Spinal nerve roots are supplied by ?

a) Anterior spinal artery

b) Posterior spinal artery

c) Ascending cervical artery

d) All of the above

Correct Answer - C

Ans. is 'c' i.e., Ascending cervical artery

Anterior and posterior spinal arteries supply spinal cord, but not spinal nerve roots.

- Spinal nerve roots are supplied by *radicular arteries* which are segmental branches of vertebral, ascending cervical, deep cervical, intercostal and sacral arteries.

Blood supply of spinal cord

1. The spinal cord receives its blood supply from :

- The anterior spinal artery
 - Two posterior spinal arteries
 - In addition to these channels the pia mater covering the spinal cord has an arterial plexus (called the arterial vasocorona) which also sends branches into the substance of the cord.
2. The main source of blood to the spinal cord is from the vertebral arteries (from which the anterior and posterior spinal arteries take origin)
- However, the blood from the vertebral artery reaches only up the cervical segments of the cord.
 - Lower down the spinal cord receive blood through radicular arteries that .These arise form spinal branches of the vertebral, ascending cervical, deep cervical, intertcostal, lumbar and sacral arteries

491. Maximum Flexion in thoracic vertebrae occurs at -

a) Upper thoracic

b) Middle thoracic

c) Lower thoracic

d) Same at all level

Correct Answer - C

Ans. is 'c' i.e., Lower thoracic

- Flexion (forward flexion) and lateral flexion (bending) -> Maximum at lower thoracic.
- Rotation - Maximum at mid-thoracic.

Flexion	Extension	Lateral flexion	Rotation
Upper thoracic - 8-9.5°	7-9-5° throughout	Upper thoracic 55-6°	Upper thoracic - 12-16°
Mid-thoracic 10- 11.5°		Mid thoracic -> 7.8-8°	Mid thoracic - 21.5-25°
Lower-thoracic: 12.5-13°		Lower thoracic - 12-13°	Lower thoracic - 8.5-12°

492. Blood supply of diaphragm is through all, except ?

a) Musculophrenic artery

b) Inferior phrenic artery

c) Middle phrenic artery

d) Pericardiophrenic artery

Correct Answer - C

Ans. C. Middle phrenic artery

- From above, the **diaphragm** receives **blood** from branches of the internal thoracic arteries, namely the pericardiophrenic artery and musculophrenic artery; from the superior phrenic arteries, which arise directly from the thoracic aorta; and from the lower internal intercostal arteries.
- From below, the inferior phrenic arteries supply the diaphragm.

493. Liver is divided into right and left lobe by all except?

a) Portal vein

b) Hepatic artery

c) Hepatic vein

d) Hepatic ducts

Correct Answer - C

Ans.is 'c' i.e., Hepatic vein

- Physiological right and left lobes are equally divided by an imaginary line running from fossa for gall bladder to the groove for IVC.
- The physiological right and left lobes have separate biliary drainage and vascular supply, i.e.
- They are supplied respectively by right and left branches of portal vein and hepatic artery and bile is conveyed by the corresponding hepatic ducts (bile ducts).

494. Dangerous area of scalp is ?

a) Superficial fascia

b) Loose areolar tissue

c) Pericranium

d) Aponeurosis

Correct Answer - B

Ans. is 'b' i.e., Loose areolar tissue

The scalp consists of five layers:

1. Skin
2. Close network of connective tissue (superficial fascia)
3. Aponeurosis (galea aponeurotica) with occipitofrontalis muscles
4. Loose areolar (subaponeurotic) tissue
5. Pericranium (outer periosteum of skull)

First three layers are intimately connected and move as one unit, and are called **surgical layers** of scalp or **scalp proper**.

Loose subaponeurotic areolar tissue (4th layer) is called **dangerous area of scalp** because it contains emissary veins through which infection in subaponeurotic space may spread readily to intracranial venous sinuses.

495. Most common cranial nerve to get compressed in increased intracranial pressure -

a) Trigeminal

b) Trochlear

c) Facial

d) Abducens

Correct Answer - D

Ans. is 'd' i.e., Abducens

- Abducent nerve is the most commonly involved nerve in increased intracranial tension and in spinal anesthesia.
- At petrous apex, abducent nerve makes a sharp bend to pass through Dorello's canal beneath Gruber's ligament.

496. Floor of Petit triangle is formed by?

a) Sacrospinalis

b) Internal oblique

c) Rectus abdominis

d) Fascia Transversalis

Correct Answer - B

Ans. is 'b' i.e., Internal oblique [Ref Text book of surgical anatomy p. 148]

Boundaries of Petit triangle (inferior lumbar triangle) are?

- Base - Iliac crest
- Anterior boundary (abdominal boundary) → Posterior border of external oblique muscle.
- Posterior boundary (lumbar boundary) - Anterior border of latissimus dorsi.
- Floor is formed by internal oblique muscle.

**497. All structures are posterior relations of
except -**

a) Appendix

b) Greater omentum

c) Psoas major

d) Femoral nerve

Correct Answer - B

Ans. is 'b' i.e., Greater omentum

Anterior

- Coils of small intestine
- Part of greater omentum (sometimes)
- Anterior abdominal wall

Posterior

- Psoas and iliacus muscles
- Femoral nerve
- Lateral cutaneous nerve of thigh
- Appendix (most common position)

498. Coverings of spermatic cord are all except ?

a) Internal spermatic fascia

b) Cremasteric fascia

c) External spermatic fascia

d) Dartos muscle

Correct Answer - D

Ans. is 'd' i.e., Dartos muscle

- The spermatic cord consists of a tubular sheath extending from the deep inguinal ring to the upper part of posterior border of testis. Constituents of spermatic cord are ?
- Ductus deferens (Vas deferens)
- Arteries :- Testicular artery, cremasteric artery, artery to ductus deferens.
- Veins :- Pampiniform plexus.
- Nerves :- Genital branch of genitofemoral nerve and sympathetic plexus around arteries.
- Others :- Lymphatics, remains of the processes vaginalis.
- Covering of spermatic cord, from within outwards, are :- (i) internal spermatic fascia, (ii) cremasteric fascia and (iii) external spermatic fascia.

499. Supracristal plane is above ?

a) Highest point of iliac crest

b) Anterior superior iliac spine

c) Posterior superior iliac spine

d) Ischeal tuberosity

Correct Answer - A

Ans.a. Highest point of iliac crest

- Supracristal plane is an anatomical transverse plane lying at the upper most part of the pelvis, the iliac crest.
- This is usually at the level of the L4 vertebrae.
- It passes through the umbilical region and the left and right lumbar regions.

500. Protective mechanism of inguinal canal ?

a) Obliquity of inguinal canal

b) Contraction of cremestric muscle

c) Contraction of conjoint tendon

d) All of the above

Correct Answer - D

Ans. is 'd' i.e., All of the above

- There are following important physiological mechanisms that protect against formation of inguinal hernia with increased intra-abdominal pressure ?
 1. Shutter mechanism :The arching fibers of internal oblique and transverse abdominis (i.e. conjoint tendon) contract when the muscles of abdomen contract. This act as a shutter on the posterior wall to protect it from herniation.
 2. Closure mechanism :In addition, contraction during shutter mechanism also narrows the deep ring due to sphincter action of transverse abdominis and internal oblique at deep inguinal ring.
 3. Obliquity of inguinal canal
 4. Ball valve action of cremestric causing plugging of inguinal canal.

501. Lateral umbilical fold of Peritoneum is produced by?

a) Median umbilical ligament

b) Medial umbilical ligament

c) Inferior epigastric vessels

d) None of the above

Correct Answer - C

Ans.is 'c' i.e., Inferior epigastric vessels

- Umbilical folds are reflections of the parietal peritoneum that are raised from the body wall by underlying structures.
- A median umbilical fold :Covers median umbilical ligament (a remnant of urachus).
- Two medial umbilical folds :Cover medial umbilical ligaments (remnants of distal part of obliterated umbilical artery).
- Two lateral umbilical folds :Cover inferior epigastric vessel.

502. Accessory organ which may be found in stomach ?

a) Spleen

b) Pancreas

c) Liver

d) Kidney

Correct Answer - B

Ans. is 'b' i.e., Pancreas

Ectopic (Accessory) pancreatic tissue may be found in submucosa of :?

- Stomach
- Meckel's diverticulum
- Duodenum
- Gall bladder
- Small intestine (jejunum, ileum)
- Spleen

503. Which upper limb muscle spans across shoulder and elbow joint?

a) Coracobrachialis

b) Biceps brachii

c) Lateral head of triceps

d) Brachialis

Correct Answer - B

Ans. is 'b' i.e., Biceps brachii

- Muscles that cross both shoulder and elbow are biceps (complete muscle, i.e. short head and long head) and triceps (only long head crosses the shoulder).

504. Subcostal nerve lies at -

a) Above 11th rib

b) Below 11th rib

c) Above 12th rib

d) Below 12th rib

Correct Answer - D

Ans. is'd'i.e., Below 12th rib

- Subcostal nerve runs along the lower border of 12th rib.
- It also supplies serratus anterior.

505. Root value of sciatic nerve

a) S1S2S3

b) L4L5S1S2S3

c) L2L3L4

d) L1L2L3

Correct Answer - B

Ans. B.L4L5S1S2S3

- Root value of sciatic nerve is L4L5S1 S2S3

506. Nerve supply of rhomboids major –

a) Spinal accessory nerve, cranial part

b) Spinal accessory nerve, spinal part

c) Dorsal scapular nerve

d) Thoracodorsal nerve

Correct Answer - C

Ans. is 'c' i.e., Dorsal scapular nerve

- Rhomboids major and minor are supplied by dorsal scapular nerve.

507. Which of the following arises from infraglenoid tubercle -

a) Longheadofbiceps

b) Longheadoftriceps

c) Shortheadofbiceps

d) Coracobrachialis

Correct Answer - B

Ans. is 'b' i.e., Long head of triceps

- Supraglenoid tubercle of scapula : origin of long head of biceps.
- Infraglenoid tubercle of scapula : origin of long head of triceps

508. Deltoid muscle causes all except –

a) Flexion of shoulder

b) Extension of shoulder

c) Internal rotation of shoulder

d) Adduction of shoulder

Correct Answer - D

Ans. is'd'i.e., Adduction of shoulder

Action of deltoid

1. Anterior (clavicular) fibres : Flexion and internal (medial) rotation of shoulder.
2. Middle (acromial) fibres : Abduction of shoulder.
3. Posterior fibres : Extension and lateral rotation of shoulder

509. Power grip of hand is due to -

a) Palmaris

b) Long flexors

c) Short flexors

d) Lumbricals

Correct Answer - B:C:D

Ans. is 'b > c & d i.e., Long flexors > Short flexors & Lumbricals

- In power grips, where considerable force may be required, the hand is used in addition to fingers.
- The flexors and extensors of wrist work strongly to fix its position, while long finger flexors and intrinsic muscles of hand work to grip the object.
- **There are four phases of power grip :-**
- Opening phase : Achieved by the synergistic muscle action of wrist flexors and finger extensors.
- Finger and thumb (optional) positioning phase : Requires extensor digitorum and intrinsic muscles of hand (lumbricals and interossei).
- Approach phase : Flexor digitorum profundus is the critical muscle.
- The muscles acting in this phase are FDP, FDS and wrist extensors. If thumb is active, thenar muscles are also involved.
- Static Grip phase : This is stabilization phase and is characterized by isometric muscle contraction and involves flexors and opposition muscles

510. Total number of dorsal interossei -

a) 2

b) 3

c) 4

d) 5

Correct Answer - C

Ans.C.4

Intrinsic muscles of Hand :

- 4 thenar muscles: Abductor pollicis brevis, flexor pollicis brevis, opponenspollicis, adductor pollicis.
- 4 hypothenar muscles: Palmaris brevis, abductor digitiminimi, flexor digitiminimi brevis, opponensdigitiminimi.
- 4 lumbricals
- 8 interossei: 4 dorsal interossei and 4 palmar interossei.

511. Division of radial nerve occurs at which level –

a) Anterior part of medial epicondyle

b) Anterior part of lateral epicondyle

c) Posterior part of medial epicondyle

d) Posterior part of lateral epicondyle

Correct Answer - B

Ans. is 'b' i.e., Anterior part of lateral epicondyle

Anterior to lateral epicondyle, the radial nerve divides into its two terminal branches :-

- .. The posterior interosseous nerve.
- ?. The superficial radial nerve.

512. Maxillary sinus epithelium is made of ?

a) Pseudostratified columnar

b) Ciliated columnar

c) Simple columnar

d) Stratified squamous non-keratinized

Correct Answer - B

Ans. is'b'i.e., Ciliated columnar

- Lining epithelium of paranasal sinuses is ciliated columnar with goblet cells.

513. Which of the following laryngeal muscle arise 4th arch

a) Cricothyroid

b) Transverse arytenoids

c) Posterior cricoarytenoid

d) Lateral arytenoids

Correct Answer - A

Ans. is 'a' i.e., Cricothyroid

- All intrinsic muscles of larynx are derived from 6th arch except cricothyroid which arises from 4th arch

514. Benedict's hand is due to injury to -

a) Ulnar nerve

b) Median nerve

c) Axillary nerve

d) Radial nerve

Correct Answer - B

Ans. is'b'i.e., Median nerve

- Benediction deformity of hand (Benedict hand) and positive Benediction test are seen in median nerve injury.

515. Outer border of pubic crest forms which structure?

a) Pubic tubercle

b) Pectin pubis

c) Anterior superior iliac spine

d) Linea terminalis

Correct Answer - A

Ans. is 'a' i.e., Pubic tubercle

- Pubic crest ends laterally in pubic tubercle

516. Lower lateral cutaneous nerve of arm is a branch of -

a) Radial nerve

b) Axillary nerve

c) Median nerve

d) Musculocutaneous nerve

Correct Answer - A

Ans. is'a'i.e., Radial nerve

- Upper lateral cutaneous nerve of arm; Branch of axillary nerve.
- Lower lateral cutaneous nerve of arm + Branch of radial nerve

517. What is the function of chordae tendineae?

a) Opens A-V valve

b) Prevents regurgitation

c) Helps contraction of papillary muscles

d) Passes action potential to papillary muscles

Correct Answer - B

Ans. is 'b' Prevents regurgitation

- The **chordae tendineae** are a group of tough, tendinous strands in the heart.
- They are commonly referred to as the “heart strings” since they resemble small pieces of string.
- Functionally, the **chordae tendineae** play a vital **role** in holding the atrioventricular valves in place while the heart is pumping blood.
- Papillary muscles contract to tighten the chordae tendineae preventing the cusps of the valves from being everted into the atrium by pressure developed by pumping action of the heart.
- This prevents regurgitation of the ventricular blood into the atrium.

518. Extraperitoneal fat is located?

a) Beneath fascia transversalis

b) Above campers fascia

c) Anterior to abdominal muscles

d) Under parietal peritoneal

Correct Answer - A

Ans. is'a'i.e., Beneath fascia transversalis

- The extra Peritoneal fat is a thin layer of connective tissue that contains a variable amount of fat and lies between the fascia transversalis and the parietal peritoneum.

519.

Thinnest bone is a part of which bone -

a) Frontal

b) Ethmoid

c) Sphenoid

d) Temporal

Correct Answer - D

Ans is 'd'i.e., Temporal

- Squamous part of temporal bone is the thinnest part of the skull (excluding orbital shelf)

520. Nucleus of trigeminal nerve is located in ?

a) Midbrain

b) Pons

c) Medulla

d) Cerebellum

Correct Answer - B

Ans. is'b'i.e.,Pons

- Cranial nerves I, II : Forebrain
- Cranial nerves III, IV : Midbrain
- Cranial nerves V, VI, VII, VIII : Pons
- Cranial nerves IX, X, XI, XII) Medulla

521. Artery forming anastomosis around surgical neck humerus -

a) 1st part of axillary artery

b) 2nd part of axillary artery

c) 3rd part of axillary artery

d) Subclavian artery

Correct Answer - C

Ans. is 'c' i.e., 3rd part of axillary artery

Anastomosis around surgical neck of humerus is formed by –

- 1. Anterior circumflex humeral artery.
- 2. Posterior circumflex humeral artery
- Both are branches of 3rd part of axillary artery.

522. Recurrent interosseous artery is a branch of -

a) Posterior interosseous artery

b) Anterior interosseous artery

c) Radial artery

d) None

Correct Answer - A

Ans. is 'a' i.e., Posterior interosseous artery

- Interosseous recurrent artery is a branch of posterior interosseous artery.

523. The costal cartilages of these ribs do not reach the sternum -

a) 11th & 12th

b) 1st & 2nd

c) 6th & 7th

d) 8th, 9th & 10th

Correct Answer - D

Ans. is'd'i.e., 8th, 9th & 10th

Ribs

- There are 12 pairs of ribs.
- All articulate posteriorly with thoracic vertebrae.
- **The ribs are divided into two types.**
- True ribs or vertebrosteral ribs :- These are 1st to 7th ribs which articulate directly with sternum through costal cartilages.
- False ribs :- These are 8th to 12th ribs and do not articulate directly with sternum.
- **False ribs can be divided into:**
- **Vertebrochantral ribs:- 8th, 9th and 10th ribs whose costal cartilages articulate with each other and with 7th costal cartilage forming costal margin**
- Floating ribs vertebral ribs :- 11th and 12th ribs have free anterior ends

524.

Which part of brain has olivary nucleus?

a) Pons

b) Midbrain

c) Spinal cord

d) Medulla

Correct Answer - D

Ans. is'd'i.e., Medulla

- Olivary nucleus is seen in medulla oblongata.

525. Patellar plexus is formed by which artery

–

a) Descending genicular

b) Anterior tibial recurrent

c) Posterior tibial recurrent

d) All of the above

Correct Answer - D

Ans. is 'd' i.e., All of the above

Anastomosis around the knee joint o It is also called as patellar network patellar anastomosis, genicular anastomose or rete articulare genus.

It is divided into two parts –

- .. Superficial plexus: Lies in superficial fascia around patella and in fat behind patella.
- 2. Deep part: Lies an femur and tibia around their adjoining articular surfaces.

It is formed by:-

A. Medial and above the condyles

- .. Descending genicular branch of femoral artery and its saphenous branch.
- 2. Superior medial genicular.

B. Medial and below the condyles

- .. Saphenous branch of descending genicular.
- 2. Inferior medial genicular.

C. Lateral and above the condyles

- .. Descending branch of lateral circumflex artery.
- 2. Superior lateral genicular.

D. Lateral and below the condyles

1. Inferior lateral genicular
2. Anterior tibial recurrent
3. Posterior tibial recurrent
4. Circumflex fibular

526. Which doesn't form the triradiate ligament of uterus?

a) Cardinal ligament

b) Ovarian ligament

c) Uterosacral ligament

d) Pubocervical ligament

Correct Answer - B

Ans. is'b'i.e., Ovarian ligament

- Triradiate ligament includes uterosacral ligament, cardinal ligament (Mackenrodt's ligament or lateral cervical ligament or transverse cervical ligament) and pubocervical ligament.

527. Gluteofemoral bursa is in between gluteus maximus and –

a) Greater trochanter

b) Lesser trochanter

c) Ischial tuberosity

d) Vastus lateralis

Correct Answer - D

Ans.'d' i.e., Vastus lateralis

- Ischial bursa: On lower and medial part of ischial tuberosity (between gluteus maximus and ischial tuberosity).
- Trochanteric bursa: On the greater trochanter (between gluteus maximus and greater trochanter).
- Gluteofemoral bursa: Between gluteus maximus and vastus lateralis.
- Iliopsoas bursa Between hip joint capsule and iliopsoas tendon.

528. Upper border of pubic ramus forms –

a) Pubic tubercle

b) Pubic symphysis

c) Arcuate line

d) Upper margin of obturator foramen

Correct Answer - C

Ans. is'i.e., Arcuate line

- Superior (upper) border of superior pubic ramus (also called pectineal line or pecten pubis) forms) Arcuate line.
- Inferior border of super pubic ramus forms > upper margin of obturator foramen

529. Arterial supply to middle 1/3rd of vagina is by ?

a) Internal pudendal artery

b) Uterine artery

c) Inferior vesical artery

d) Middle rectal artery

Correct Answer - C

Ans. is 'c' i.e., Inferior vesical artery

- Arterial supply of vagina
- Vaginal branch of internal iliac (main supply)
- Cervicovaginal branch of uterine artery (in upper part).
- Middle rectal and internal pudendal arteries (in lower part).
- Inferiorvesical artery (in middle 3rd).

530. What is true about adductors of thigh –

a) Ischial head of adductor magnus is an adductor

b) Profunda femoris artery is the main blood supply

c) Ischial head of adductor magnus originates from adductor tubercle

d) Adductor magnus is the largest muscle

Correct Answer - D

Ans. is'd'i.e., Adductor magnus is the largest muscle

- Ischial head of adductor magnus is a hamstring muscle (not adductor).
- Ischial head of adductor magnus originates from inferolateral aspect of Ischial tuberosity (not from adductor tubercle).
- Main artery of adductor (medial) compartment of thigh is obturator artery (not profunda femoris).
- Adductor magnus is the largest muscle of the adductor compartment.

531. Profunda femoris artery at its origin lies on which side of the femoral artery ?

a) Medial

b) Lateral

c) Posterior

d) Posteromedial

Correct Answer - B

Ans. is 'b' i.e., Lateral

- Profunda femoris artery arises from lateral side of femoral artery about 4 cm below the inguinal ligament.

532. Fundus of gall bladder at which vertebral level

a) L1

b) L3

c) S1

d) S3

Correct Answer - A

Ans. is'a'i.e., L1

- Transpyloric plane passes anteriorly through tips of 9th costal cartilage and posteriorly through lower border of L1 vertebrae.
- Organs present at this level are hilum of kidney, pylorus of stomach, beginning of duodenum, neck of pancreas, fundus of gall bladder, and origin of superior mesenteric vessel.

533. Patellar plexus is formed by ?

a) Medial cutaneous nerve of thigh

b) Lateral cutaneous nerve of thigh

c) Posterior cutaneous nerve of thigh

d) Intermediate cutaneous nerve of thigh

Correct Answer - A

Ans. is 'a' i.e., Medial cutaneous nerve of thigh

- Medial cutaneous nerve of thigh joins the branches of saphenous nerve to form patellar plexus and subsartorial plexus

534. Root value of median cutaneous nerve of thigh is ?

a) L1,L2,L3

b) L2-L3

c) L3-L4

d) L4-L5

Correct Answer - B

Ans. is'b'i.e., L2-L3

- Medial femoral cutaneous nerve (medial cutaneous nerve of thigh) is a branch of anterior division of femoral nerve (L1, L2).

535.

Pudendal canal is a part of -

a) Colle's fascia

b) Obturator fascia

c) Scarpa's fascia

d) None

Correct Answer - B

Ans. is'b'i.e., Obturator fascia

- Pudendal canal (Alcock's canal) is a fascial canal in the lateral wall of ischioanal (ischio-anal) fossa.
- It is a space between obturator fascia and lunatic fascia. Other believe that it is formed by splitting of the obturator fascia.

Contents of pudendal canal are –

1. Pudendal nerve,
2. Internal pudendal artery, and
3. Internal pudendal vein.